



Volume 7 Issue 4,  
April 2021

### Copyright

©2021 Nadia AlDhaheeri et.al. This is an open access article distributed under the terms of the Creative Commons Attribution License, which permits unrestricted use, distribution, and reproduction in any medium, provided the original author and source are credited



### Citation

Nadia AlDhaheeri et.al (2021), A Comparison of Treatment Effects of Forsus and SUS<sup>2</sup> appliances in patients with Class II division 1. *Int J Dent & Ora Hea*. 7:4.

ISSN 2471-657X

Published by  
Biocore Group |  
[www.biocoreopen.org/ijdo/archive.php](http://www.biocoreopen.org/ijdo/archive.php)

# International Journal of Dentistry and Oral Health

## Case Report

### A Comparison of Treatment Effects of Forsus and SUS<sup>2</sup> Appliances in Patients With Class II division 1

Haya AlEid<sup>1</sup>, Ahmed AlAsmari<sup>1</sup>, Nadia AlDhaheeri<sup>2</sup>, Rabab AlTuwaيري<sup>2</sup>

<sup>1</sup> *Orthodontic resident, King Saud Medical City, Saudi Arabia.*

<sup>2</sup> *Consultant orthodontist, King Saud Medical City, Saudi Arabia.*

**Corresponding author:** Ahmed AlAsmari

Orthodontic resident, King Saud Medical City, Saudi Arabia.

E-mail: [drahmed1410@gmail.com](mailto:drahmed1410@gmail.com)

**Article History:** Received: April 15, 2021;  
Accepted: April 22, 2021;  
Published: April XX, 2021.

### Declaration of Conflicting Interest

The author(s) declared no potential conflicts of interest with respect to the research, authorship, and/or publication of this article.

### Introduction

Class II malocclusion is the most common sagittal problem in the united states.\*1 Within Saudi population, Class II malocclusion is prevalent in 16.4% \*3

According to McNamara, mandibular retrusion is the most common contributing factor of Class II malocclusion.\*2 There are many appliances and techniques to treat class II malocclusion, it could be fixed or removable, including inter-arch appliances, extra-oral appliances, extraction, and surgical correction for severe cases. Numerous fixed inter-arch appliances (compliance-free) are available. They typically move mandibular molars mesially and show tipping of the mandibular incisors, and variable effects associated with mandibular growth.

Forsus Fatigue Resistant Device (FRD) (3M Unitek Corp, Monrovia, Calif). Is a three- piece, semirigid telescoping system incorporating a superelastic nickel-titanium coil spring. It can be used in combination with comprehensive fixed appliances. The FRD attaches at the maxillary first molar headgear tube and onto the mandibular archwire, distal to either the cuspid or bicuspid bracket.\*4

The Sabbagh Universal Spring (SUS, Dentaurum, Germany) The SUS2 consists of a telescopic rod fitted into a guide tube. Inside the guide tube is a spring that can be adjusted to deliver different force levels, depending on the severity of the Class II malocclusion. Its U loop is designed to fit into the maxillary first molars while the lower end is tied to the archwire between the first premolar and the canine, or even between the canine and the lateral incisor.\*5

Unlike the Forsus, the SUS2 does not have a left or right side, it is a true universal spring. External springs can be added on to the appliance to increase its springiness.

The aim of this case report is to present the effect of FRD and SUS2 on class II division 1 growing patients with increased overjet and overbite.

### Case 1

12 years old Saudi Female presented to Orthodontic clinic with chief complaint "My front teeth are sticking out". Not aware or complaining of any disease nor taking any medication, no previous hospitalization, no known allergies or syndromes reported. She is not reporting any habit and brushing her teeth twice a day. She reported chipped off tooth related to #11 after falling since 4 years ago. She has multiple restorations and visited the dental office 3 months ago for scaling.

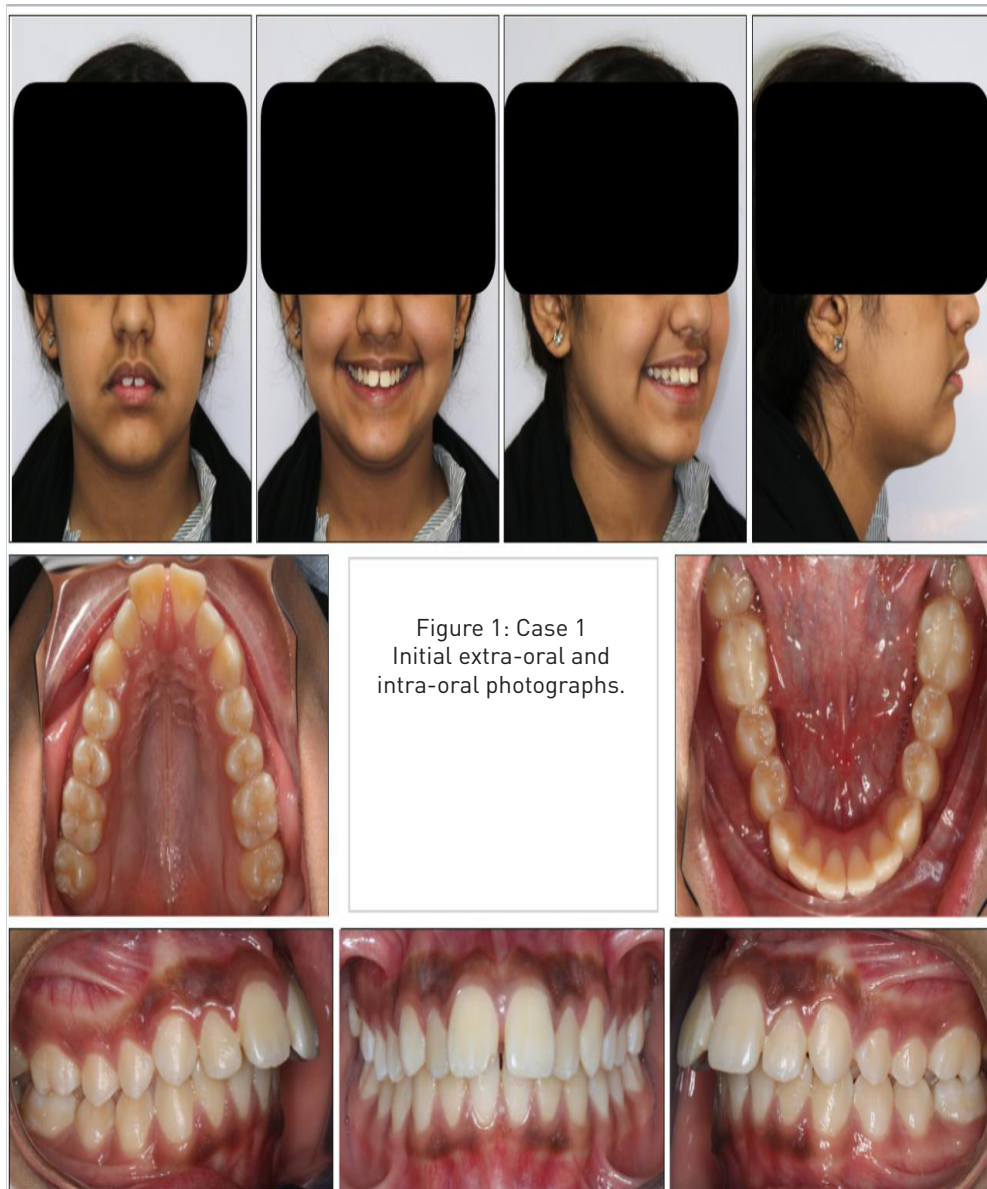
### Extra-Oral Examination

Normal looking, healthy body built, mesofacial form with slightly convex profile, fairly symmetrical face, average lower anterior facial height, 4mm incisal show at rest with average smile line, normal lip length and morphology with incompetent lips, protruded upper lip and retruded and everted lower lip, upper

dental midline coincide with the facial midline, average nasolabial angle, deep labiomental fold, normal cervico-mental angle, wide buccal corridors, with non-consonant smile arc.

#### Intra-Oral Examination

Good oral hygiene, high maxillary labial frenum attachment, no clinically detectable caries, Chipped off enamel related to the mesio-incisal area of tooth #11. (Figure 1)



#### Study cast analysis

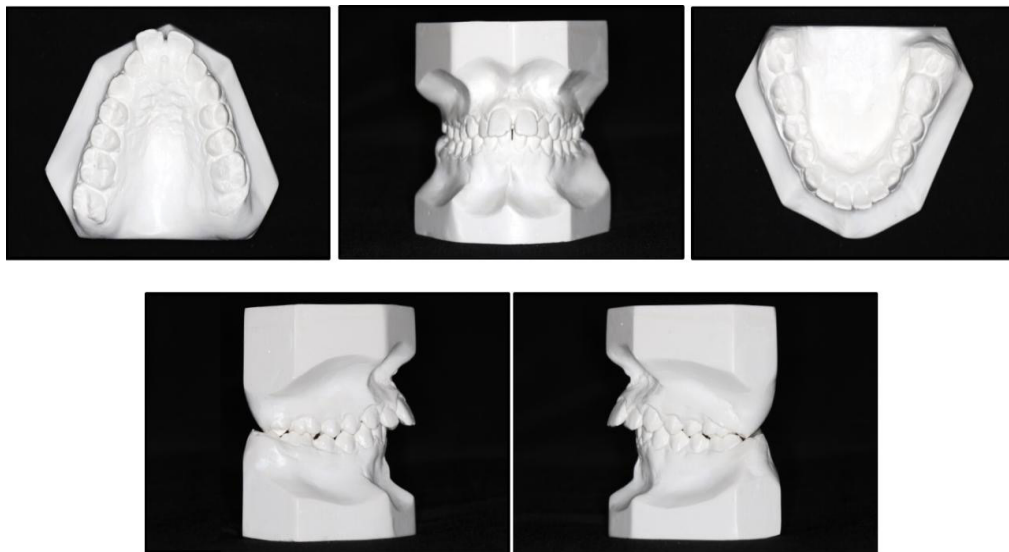
##### Intra-arch Findings

**Maxillary:** Symmetrical tapered V-shaped arch, normal compensating curve, 2mm spacing.

**Mandibular:** Symmetrical Ovoid shaped arch, deep curve of Spee, 1mm spacing.

##### Inter-arch Findings

Class II division 1 malocclusion, class II (full unit) molar/canine relationships on both sides, class II division I incisor relationship, 8mm overjet recorded from #11, 4mm (50%) overbite, lower dental midline coincide with the upper dental midline, no Bolton discrepancy. (Figure 2)



**Figure 2** Case 1 Initial Model Photographs.

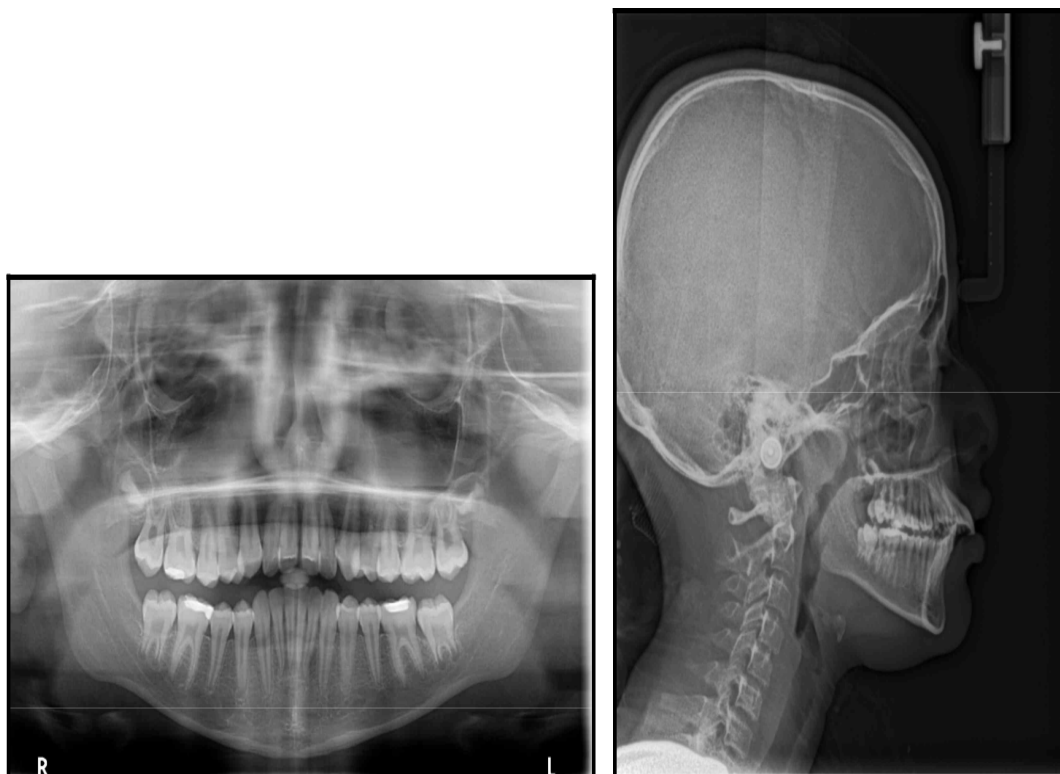
### **Radiographic Analysis**

#### **OPG**

Condyles, mandibular rami, body of the mandible, and maxillary sinuses are all within normal, all teeth are present except of #38,48 are congenitally missing. Teeth #18,28 are at developing stage. Normal bone level and trabeculation. (Figure 3A)

#### **Cephalometric Analysis**

Class II skeletal relationship due to retrognathic mandible, retruded chin, normal lower facial proportion, proclined and protruded upper incisors and normally inclined lower incisors, normal nasolabial angle, protruded upper lip and retruded and everted lower lip. (Figure 3B)



**Figure 3** Case 1 (A) Pre-treatment OPG Radiograph.  
(B) Pre-treatment Lateral Cephalometric Radiograph.

## Diagnosis

Class II division 1 dental malocclusion on a class II skeletal base due to retrognathic mandible with increased overjet and overbite. Problem list and treatment objectives are summarized in Table 1.

Problem list	Treatment objectives
<ul style="list-style-type: none"> <li>- General:                             <ul style="list-style-type: none"> <li>• High maxillary labial frenum attachment.</li> </ul> </li> <li>- Skeletally:                             <ul style="list-style-type: none"> <li>• Class II skeletal relationship due to retrognathic mandible.</li> </ul> </li> <li>- Dentally:                             <ul style="list-style-type: none"> <li>• Class II (full unit) molar/canine relationship on both sides.</li> <li>• Proclined and protruded upper incisors.</li> <li>• Increased overjet and overbite.</li> <li>• Deep curve of Spee.</li> </ul> </li> <li>- Soft tissue:                             <ul style="list-style-type: none"> <li>• Convex profile.</li> <li>• Protruded upper lip, retruded and everted lower lip.</li> <li>• Deep labiomental fold.</li> <li>• Wide buccal corridors.</li> <li>• Incompetent lips.</li> </ul> </li> <li>- Intra-arch:                             <ul style="list-style-type: none"> <li>• Spacing in upper and lower arches.</li> <li>• Multiple rotated teeth.</li> </ul> </li> </ul>	<ul style="list-style-type: none"> <li>• Improve sagittal relationship.</li> <li>• Achieve class I molar and canine relationships.</li> <li>• Improve upper incisors inclination and position.</li> <li>• Normalize overjet and overbite.</li> <li>• Improve soft tissue profile and lip competency.</li> <li>• Close upper and lower spaces, eliminate rotations, coordinate arches.</li> </ul>

**Table 1**

## Treatment progress

Treatment started by banding of all first molars and bonding of all other teeth using 0.022 slot Roth prescription brackets.

Start leveling and alignment with 0.014- inch Ni-Ti and continued with 0.016-inch Ni-Ti, 0.016 × 0.022-inch Ni-Ti, 0.016 × 0.022-inch stainless steel (SS), 0.017 × 0.025-inch SS, and 0.019 × 0.025-inch SS archwires, respectively. Leveling and alignment were completed in 5 months and at the end of this phase the arch was built up and expanded by the archwires.

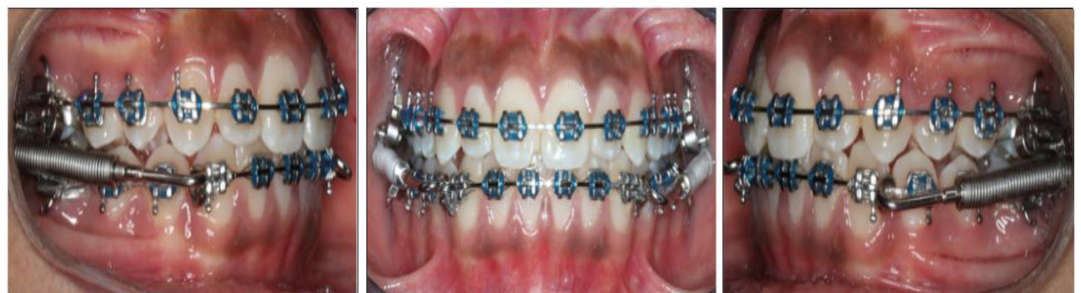To prepare the lower arch for Forsus FRD, tight ligation of the arch from molar to molar under 0.019 × 0.025-inch SS archwire, and cinchback of the wire.

Forsus (EZ2) appliance inserted and the lower parts were placed distal to the mandibular canine teeth and steel ligate the canines brackets to prevent rotation or debonding.

Class III molar relationships achieved after 3 months activation of Forsus, overjet and overbite was overcorrected. The Forsus FRD was removed and occlusion detailing and settling began. Patient was referred to Periodontal clinic for Frenectomy one month before debonding.

## Retention

During the retention period, the patient was instructed to wear Hawley retainer + fixed lingual 1-1 in the upper arch, and fixed lingual retainer 3-3 in the lower arch.



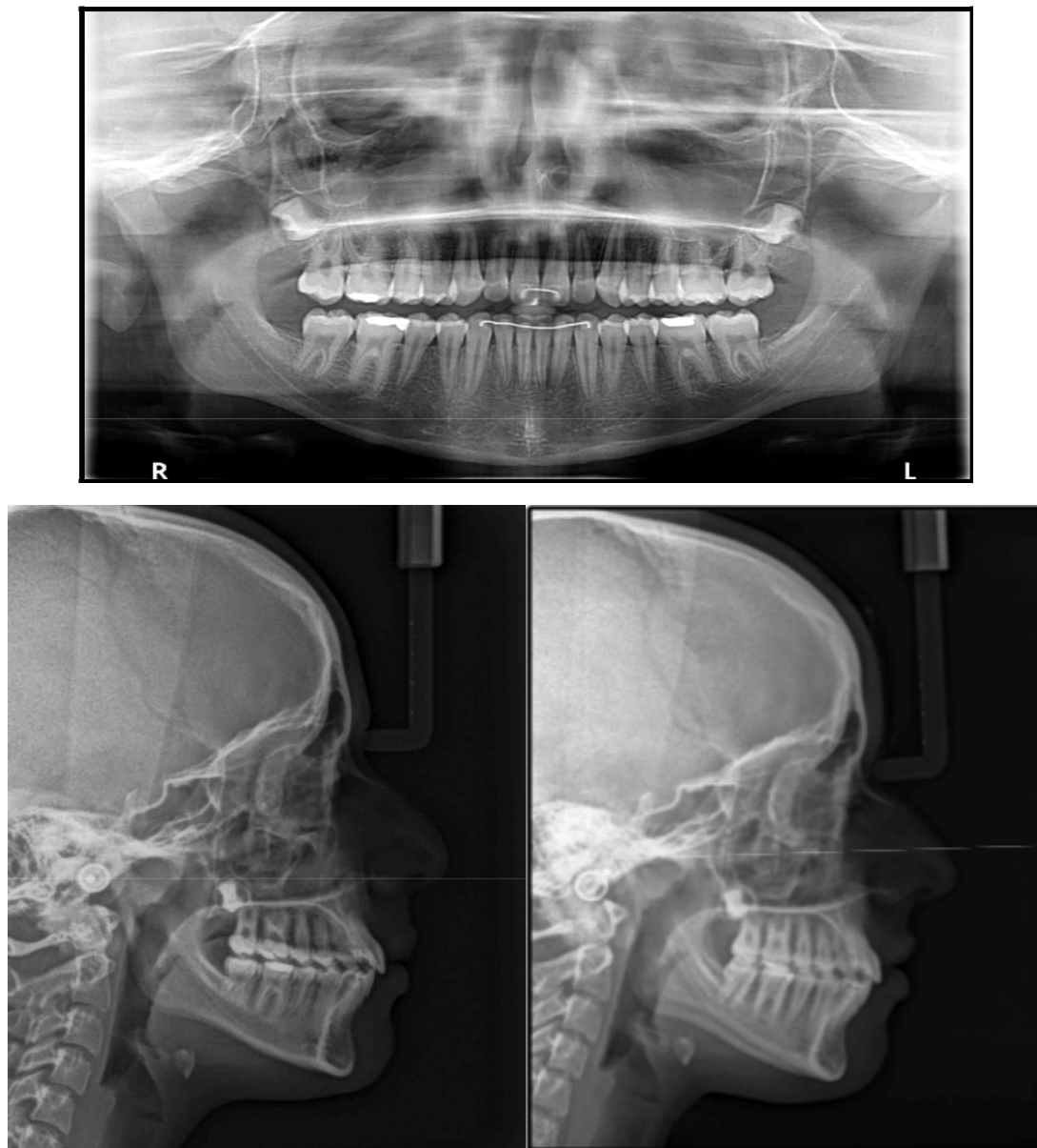
**Figure 4** Case 1 Progress intra-oral photographs after application of the Forsus FRD.

**Treatment result**

Cephalometric measurements at the pre-treatment, post-treatment and post-retention (1 year follow-up) periods are given in **Table 2**. It shows improvement in skeletal and dental parameters. Class I molar/canine relationship achieved. Overbite decreased from 4mm to 2mm and overjet decreased from 8mm to 2mm (**Figure 6**). ANB angle decreased from 4.6o to 0.9o. Convexity decreased and the deep labiomenal fold has improved (**Figure 5 (B)**). Cephalometric superimposition using Bjork and Skiller structured superimposition method showed in **Figure 8** indicated no significant change in point A and forward and downward movement of point B. Upper incisors moved backward and upward, upper molars moved backward. Lower incisors moved forward and lower molars moved forward and upward. The post-treatment panoramic radiograph (**Figure 5 (A)**) showed no alveolar bone loss or apical root resorption. Post-treatment follow-up were carried out after 1 year. Intra-oral photographs showed that teeth were well aligned and the occlusion was stable (**Figure 7**). Cephalometric measurements indicated that no significant changes occurred (**Figure 5 (C)**), (**Table 2**). Upper third molars were at developing stage so extraction was deferred.

		Measurement	Mean (±Sd)	Patient		
				Initial	Final	1 year retention
Skeletal	Anterior	SNA (°)	82 ° (±2)	79.9°	79.2°	79.4°
		SNB (°)	80 ° (±2)	75.3°	78.3°	78.6°
		ANB (°)	2 ° (±1.7)	4.6°	0.9°	0.8°
		Wits (mm)	M = -1.17 (±1.9) F = - 0.10 (±1.77)	2.8mm	-2.1mm	-2.5mm
		SNPog	80 ° (±3)	74.5°	75.8°	76.3°
		Angle of Convexity NA-APg (°)	0 ° (±5.1)	7°	4°	4°
	Vertical	SN-PP	8 ° (±3)	11.1°	9.2°	9.1°
		SN-MP	32 ° (±5.1)	36.4°	37.3°	37.7°
		PP-MP	25 ° (±3)	22.6°	25.2°	27.5°
		Me-tGo-Ar	126 ° (±10)	125°	127°	128.4°
		LAFH (ANS to Gn ÷ N to Gn)	0.55 (±0.03)	0.58 (58%)	0.60 (60%)	0.61 (61%)
		Y Axis (N-S-Gn)	59.4 ° (±3.8)	63°	64°	66°
Dental		U1 - L1 (°)	131° (±5)	111.3°	126.5°	126.1°
		U1 - SN	104° (±2)	116.5°	103.4°	103.5°
		U1 - Palatal Plane (°)	110 ° (±6)	122.4°	109.5°	109.3°
		U1 - NA (°)	22 ° (±5.7)	38.4°	24.6°	25.0°
		U1 - NA (mm)	4mm (±2.7)	9.4mm.	7mm	7.4mm
		L1 - NB (°)	25 ° (±6)	26.5°	28.1°	28.5°
		L1 - NB (mm)	4 (±1.8)	4.9mm.	5.5mm	5.6mm
		L1 - APg (mm)	1 (±2)	2.8mm.	3.7mm	3.9mm
Soft Tissue		UL - EL	-4 mm (±2)	1mm	-3mm	-4mm
		LL - EL	0 mm (±2)	2mm	-1mm	-1mm
		UL - SnV	2 mm	3mm	1mm	1mm
		LL - SnV	-2 mm	-2 mm	0mm	0mm
		Pog - SnV	-4 mm	-7mm	-4mm	-4mm
		Nasolabial angle (°)	90 - 110 °	100.9°	109.2°	108.9°

**Table 2**



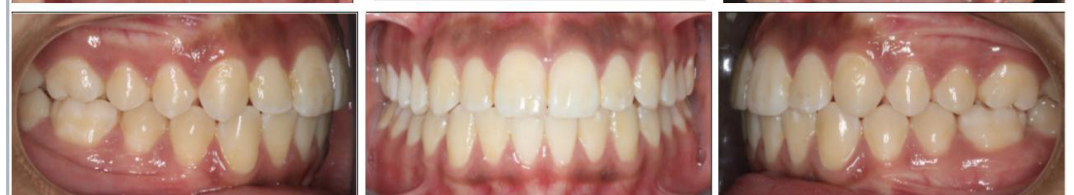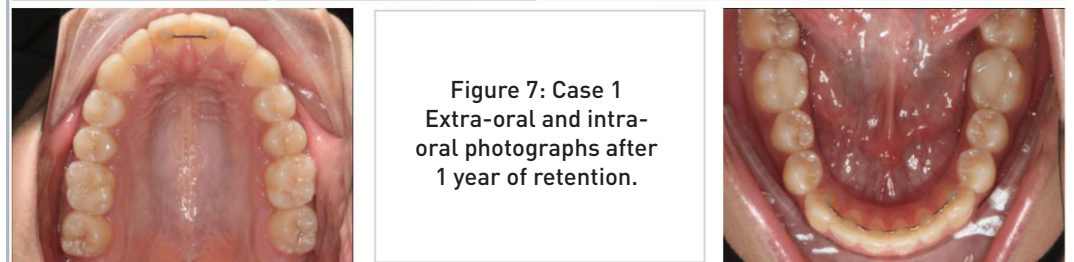
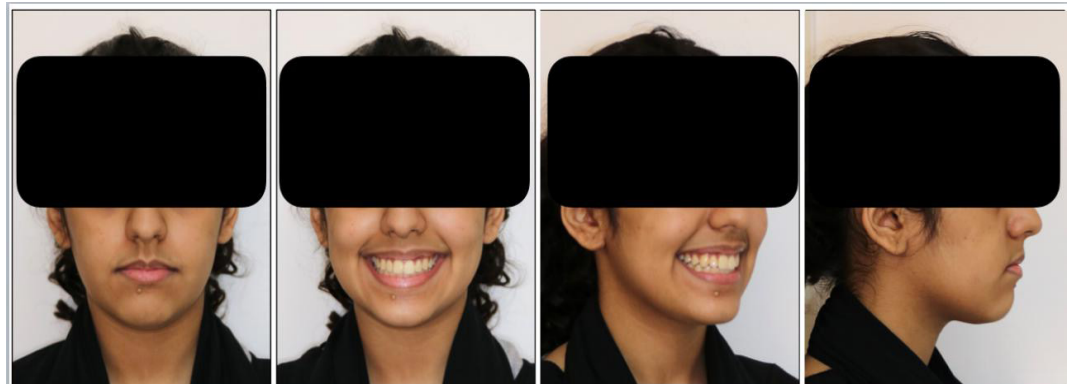
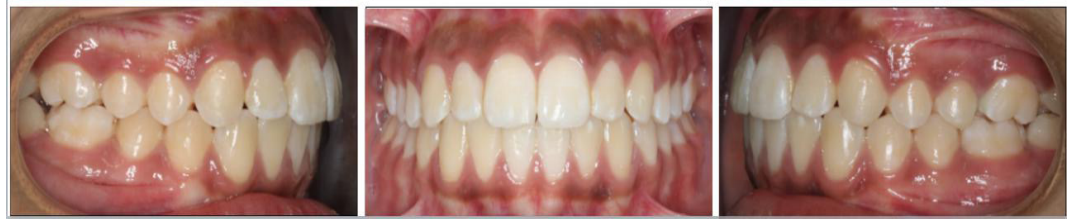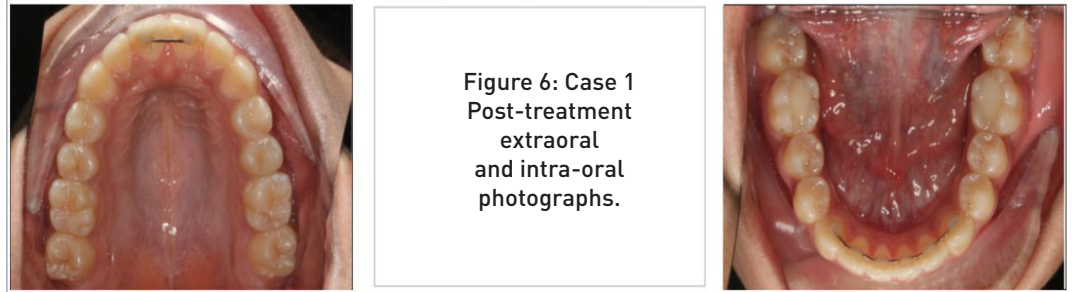
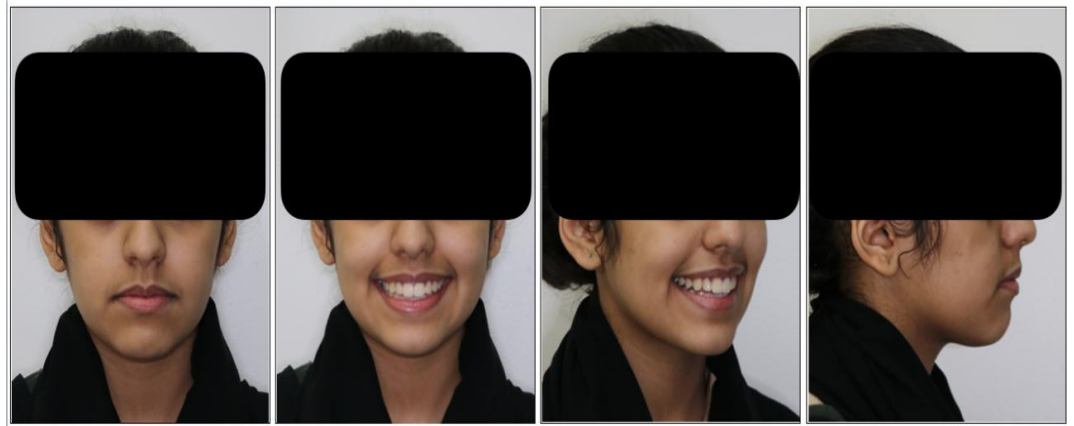
**Figure 5** Case 1 (A) Pos-treatment OPG Radiograph.  
(B) Post-treatment Lateral Cephalometric Radiograph.  
(C) Post-retention (1 year follow up) Lateral Cephalometric Radiograph.

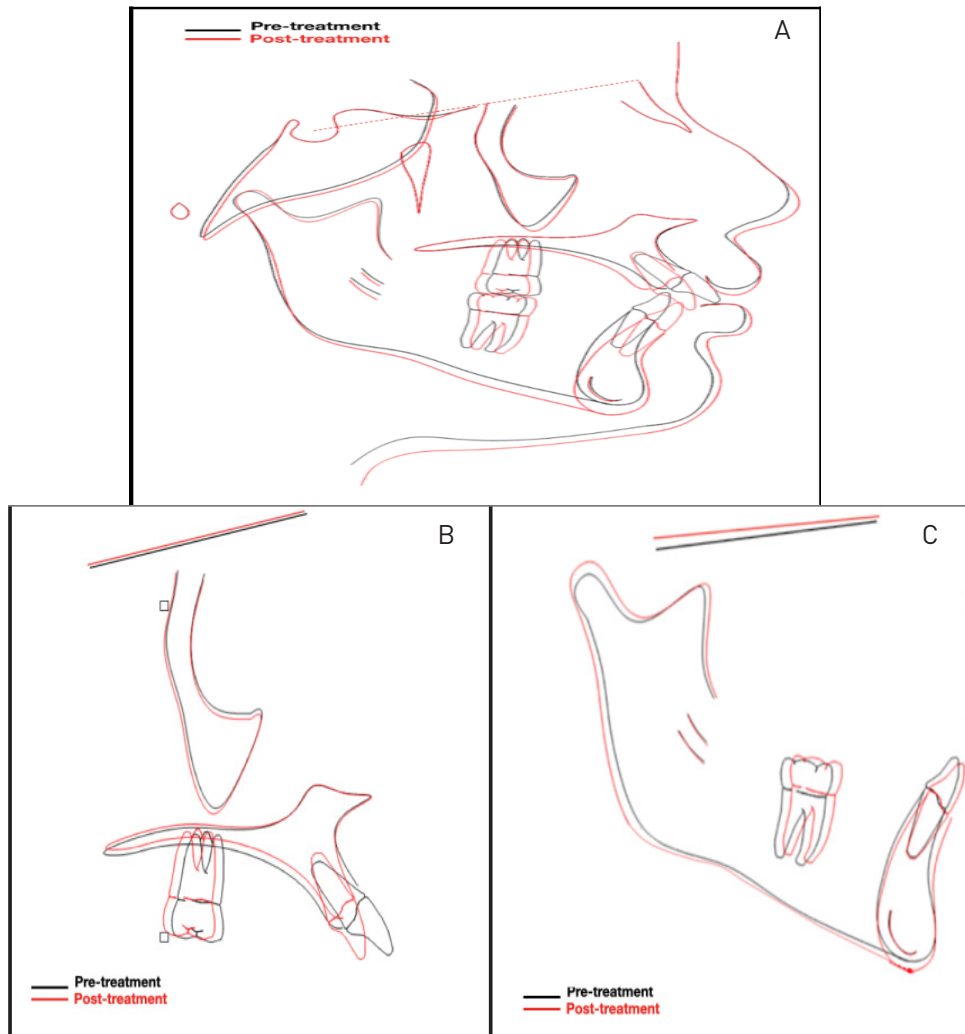
### **Case 2**

14 years old Saudi Male presented to Orthodontic clinic with chief complaint "I don't like the prominence of my front teeth". Not aware or complaining of any disease nor taking any medication, no previous hospitalization, no known allergies or syndromes reported. He is not reporting any habit and brushing her teeth twice a day. He has multiple restorations and visited the dental office 3 months ago for scaling.

### **Extra-Oral Examination**

Normal looking, healthy body built, mesofacial form with convex profile, fairly symmetrical face, average lower anterior facial height, no incisal show at rest with average smile line, normal lip length and morphology with competent lips, protruded upper and lower lips related to E line, upper dental midline coincide with the facial midline, average nasolabial angle, deep labiamental fold, obtuse cervico-mental angle, average buccal corridors, with consonant smile arc. (Figure 9)





**Figure 8** Case 1 Cephalometric superimposition using Bjork and Skiller structured superimposition method.

A) Superimposition on the anterior part of sella turcica.

B) Superimposition on the anterior surface of zygomatic process of maxilla.

C) Superimposition on the anterior surface of the anterior contour of the chin and mandibular canal.

### Intra-Oral Examination

Good oral hygiene, normal labial frenum attachment, no clinically detectable caries. (Figure 9)

### Study cast analysis

#### Intra-arch Findings

**Maxillary:** Ovoid shaped arch, normal compensating curve, 2mm crowding.

**Mandibular:** Ovoid shaped arch, deep curve of Spee, 3mm crowding.

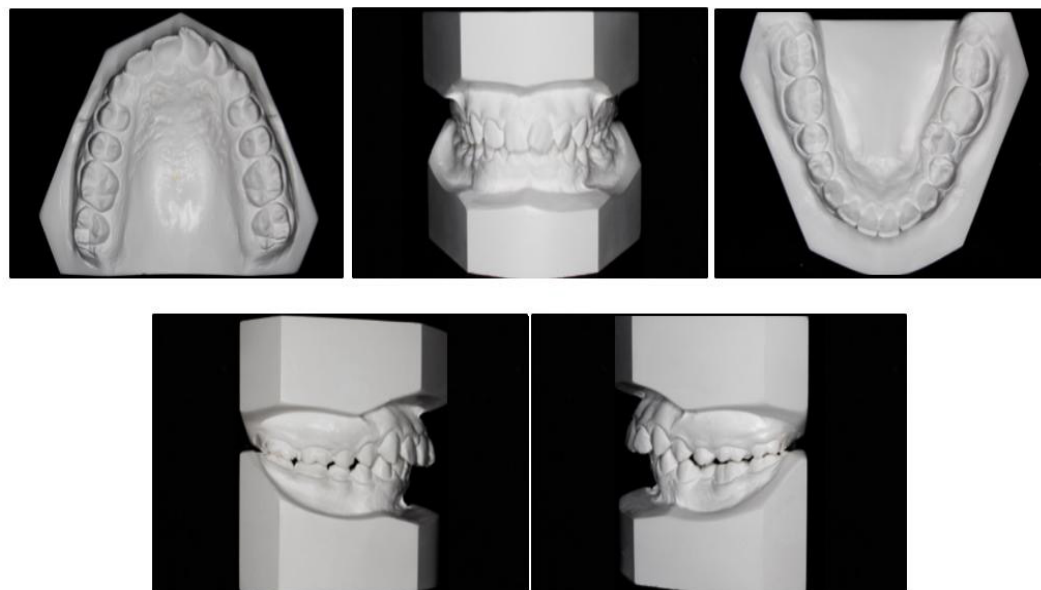
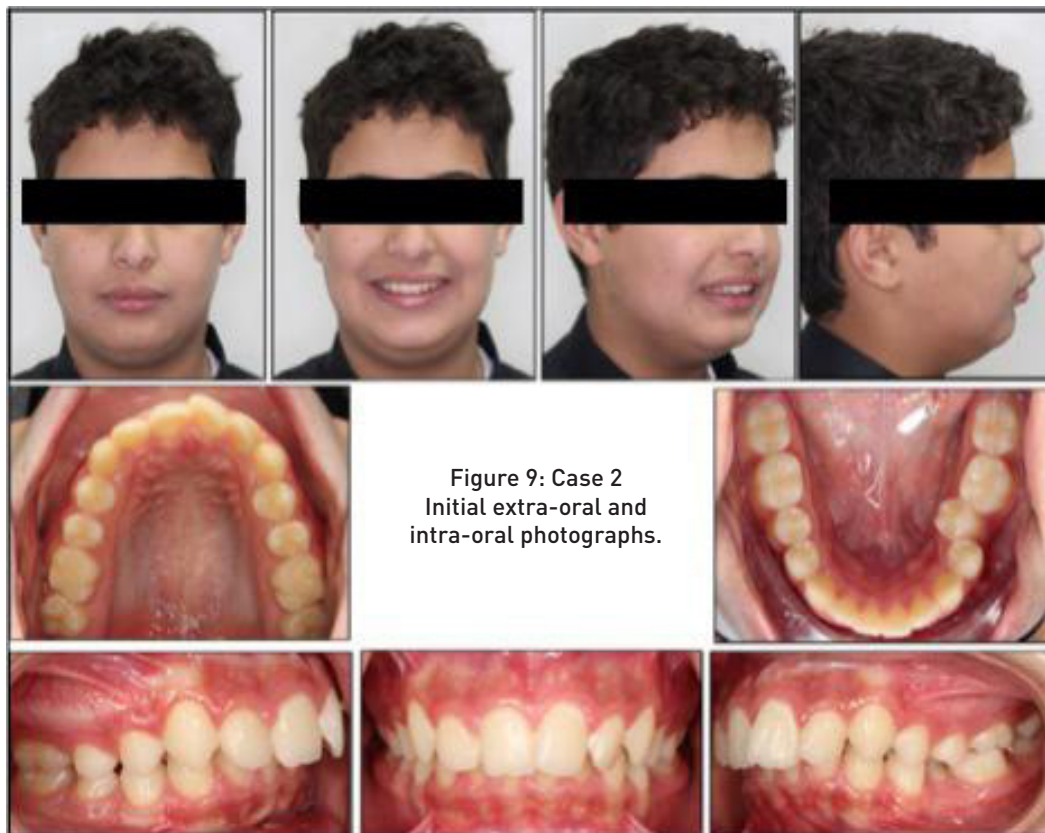#### Inter-arch Findings

Class II division 1 malocclusion, class II (half unit) molar/canine relationships on both sides, class II division I incisor relationship, 7mm overjet recorded from #11, 6mm (80%) overbite, lower dental midline coincide with the upper dental midline, no Bolton discrepancy.

### OPG

Condyles, mandibular rami, body of the mandible, and maxillary sinuses are all within normal, all teeth are present, upper and lower third molars are at developing stage. Normal bone level and trabeculation. (Figure 11 (A))

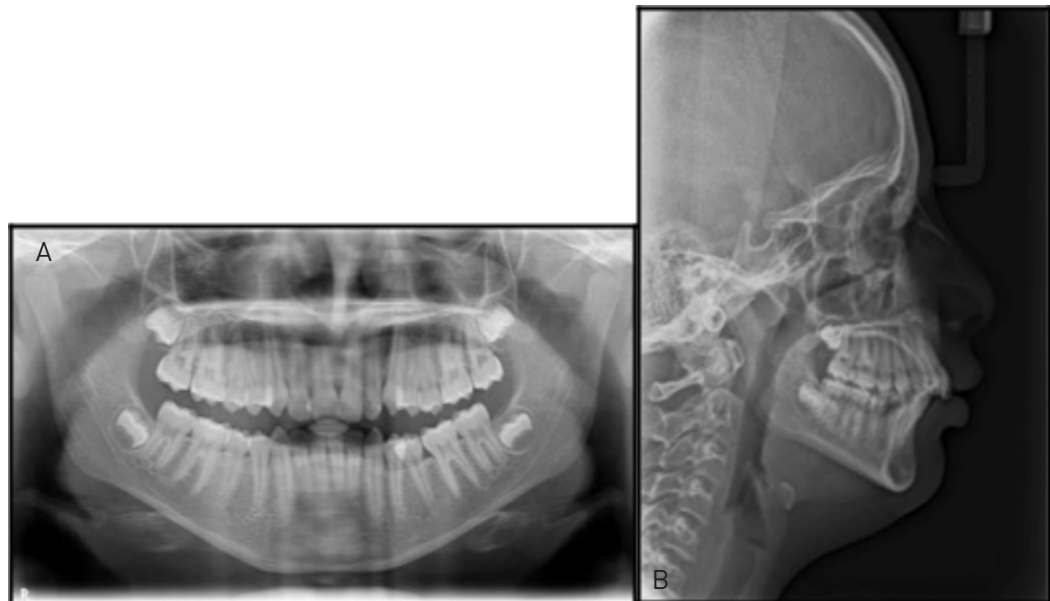




**Figure 10** Case 2 Initial model photographs.

**Cephalometric analysis**

Class II skeletal relationship due to retrognathic mandible, retruded chin, normal lower facial proportion, Normally inclined and positioned upper and lower incisors, normal nasolabial angle, protruded upper and lower lips related to E line. (Figure 11 (B))



**Figure 11** Case 2 (A) Pre-treatment OPG Radiograph.  
(B) Pre-treatment Lateral Cephalometric Radiograph.

### Diagnosis

Class II division 1 dental malocclusion on a class II skeletal base due to retrognathic mandible with increased overjet and overbite. Problem list and treatment objectives are summarized in Table 3.

Problem list	Treatment objectives
<ul style="list-style-type: none"> <li>- Generally:                             <ul style="list-style-type: none"> <li>• Thin attached gingiva.</li> </ul> </li> <li>- Skeletally:                             <ul style="list-style-type: none"> <li>• Class II skeletal relationship due to retrognathic mandible.</li> </ul> </li> <li>- Dentally:                             <ul style="list-style-type: none"> <li>• Class II (half unit) molar/canine relationship on both sides.</li> <li>• Increased overjet and overbite.</li> <li>• Deep curve of Spee.</li> </ul> </li> <li>- Soft tissue:                             <ul style="list-style-type: none"> <li>• Convex profile.</li> <li>• Protruded upper and lower lips</li> <li>• Deep labiomentral fold.</li> <li>• Obtuse chin throat angle</li> </ul> </li> <li>- Intra-arch:                             <ul style="list-style-type: none"> <li>• Crowding in upper and lower arches.</li> <li>• Multiple rotated teeth.</li> <li>• Lingual tipped #35</li> </ul> </li> </ul>	<ul style="list-style-type: none"> <li>• Improve sagittal relationship.</li> <li>• Achieve class I molar and canine relationships.</li> <li>• Improve upper incisors inclination and position.</li> <li>• Normalize overjet and overbite.</li> <li>• Improve soft tissue profile</li> <li>• Referral to peiodontist for consultation and management</li> <li>• Alleviate crowding and lingual tipped #35</li> </ul>

**Table 3**

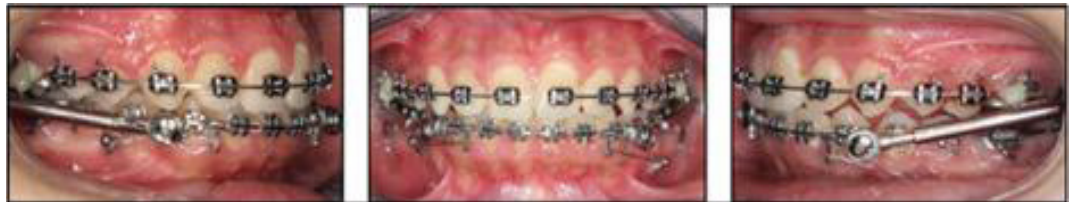### Treatment progress

Treatment was initiated using 0.016" NiTi in both arches, which was followed by 0.016" × 0.022" NiTi and 0.017" × 0.025" NiTi. Also, a 0.019" × 0.025" stainless steel wire with crimpable hooks distal to lower lateral incisors was placed as a working arch wire. The wires were cinched distal to the maxillary and mandibular second molars. Full ligation of the lower dental arch was achieved. Leveling and alignment were completed in 9 months. The miniscrews (Unitek™ 3M United States / 1.8 x 8 mm) were placed bilaterally between lower first and second premolars under drops of local anesthesia. Lacebacks were placed through the mini screws to crimpable hooks and the size of the ligature wire used was 0.010-inch. Ligature wire attached to miniscrews applied a distal driving force on the lower anteriors, which minimized the lower incisor proclination. It also allowed maxillary arch distalization resulting in mandibular arch correction.

Bilateral fixed class II corrector SUS2 appliance were adjusted and attached from maxillary first molars to distal mandibular canines. It produces close to 244g of force when springs are fully compressed (Figure 12) \*5. Recall visits were scheduled every four weeks and an activation by slotted spacers crimped on the telescope rod was performed, if needed. The SUS2 appliance was maintained in place for 6 months. The patient showed compliance with the SUS2 appliance treatment, no recorded breakage of appliance or brackets. Class I molar and canine relation with optimum overbite and overjet was achieved. The SUS2 appliance and TADs were removed. Finishing and detailing procedures were accomplished using 0.019" × 0.025" NiTi arch wires with settling elastics over 3 months. the appliance was debonded after the total treatment of 24 months.

### Retention

At the end of treatment, Hawley retainer in upper arch with anterior bite plane and fixed retainer from 3-3. In lower arch Wraparound retainer with fixed retainer from 3-3.



**Figure 12** Case 2 Progress intra-oral photographs, TAD supported SUS appliance.

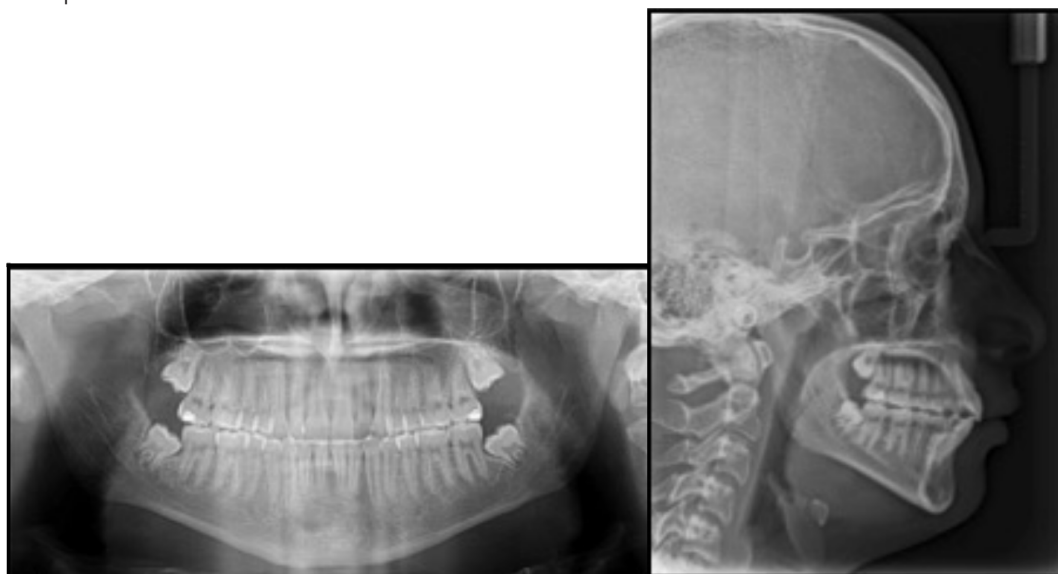
### Treatment result

Cephalometric measurements at the pre-treatment, post-treatment are given in Table 4. It shows improvement in skeletal and dental parameters.

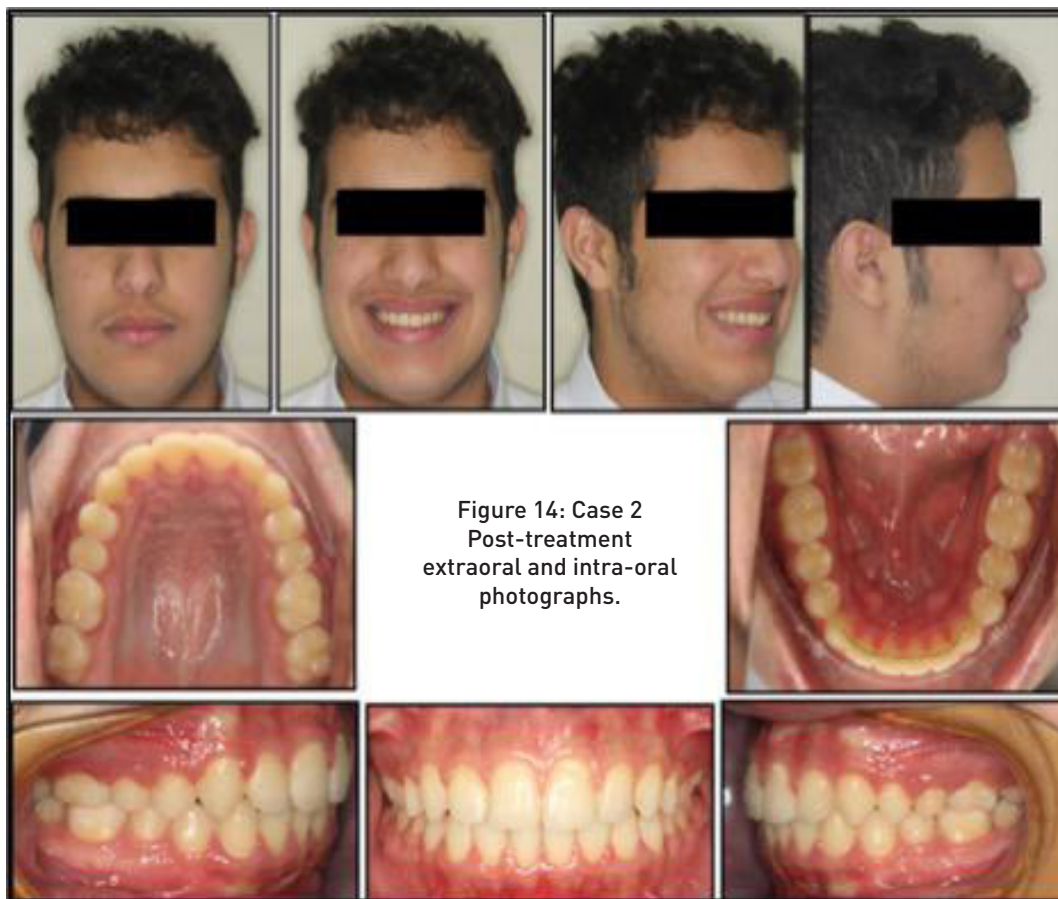	Mean	Pre-treatment	Post-Treatment
SNA	82° ± 2°	80°	80°
SNB	78° ± 2°	75°	78°
ANB	2° ± 2°	5°	2°
NA-APog	0° ± 5°	9°	4°
SN-Pog	80° ± 3°	76°	79°
Wits Appraisal	-1mm/ 0mm	2 mm	1 mm
SN-MP	32° ± 5°	39°	41°
SN-PP	8° ± 3°	17°	18°
PP-MP	25° ± 3°	22°	25°
Co-A		88 mm	88 mm
Co-Gn	111-114 mm	108 mm	111 mm
ANS-ME/N-ME	55 ± 3%	57%	59%
U1-L1	131° ± 5°	126°	124°
U1-SN	104° ± 2°	106°	100°
U1-PP	110° ± 6°	116°	110°
U1-NA	22°	20°	18°
U1-NA (MM)	4 mm	4 mm	2 mm
L1-NB	25°	28°	28°
L1-NB (MM)	4mm	5 mm	5 mm
L1-Pog (MM)	1mm± 2mm	2 mm	2 mm
L1-MP	93°±6°	94°	94°
UL-E Line	-4 mm± 2mm	3 mm	-2 mm
LL-E Line	-2 mm± 2mm	2 mm	0 mm
NLA	90°-110°	92°	94°

**Table 4**

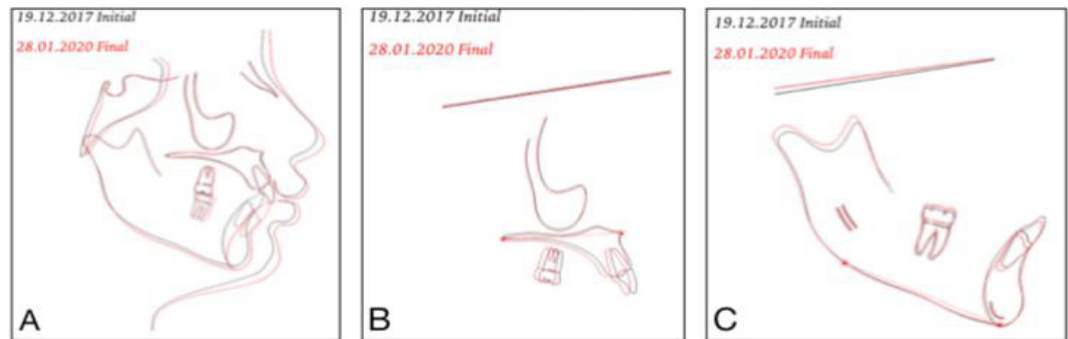
Class I molar/canine relationship achieved. Overbite decreased from 6mm to 2mm and overjet decreased from 7mm to 2mm (Figure 14). ANB angle decreased from 5o to 2o. Convexity decreased and the deep labiomentental fold has improved (Figure 13 (B)). Cephalometric superimposition using Bjork and Skiller structured superimposition method showed in Figure 15 indicated no significant changes in point A and 2mm forward and downward movement of point B. Upper incisors Retruded 2 mm and retroclined 6°, upper molars Moved distally 2 mm. Lower incisors Intruded 2 mm and lower molars Extruded 1 mm. The post-treatment panoramic radiograph (Figure 13 (A)) showed no alveolar bone loss or apical root resorption.



**Figure 13** Case 2 (A) Pos-treatment OPG Radiograph.  
(B) Post-treatment Lateral Cephalometric Radiograph.



**Figure 14:** Case 2  
Post-treatment  
extraoral and intra-oral  
photographs.



**Figure 15** Case 2 Cephalometric superimposition using Bjork and Skiller structured superimposition method.  
 A) Superimposition on the anterior part of sella turcica.  
 B) Superimposition on the anterior surface of zygomatic process of maxilla.  
 C) Superimposition on the anterior surface of the anterior contour of the chin and mandibular canal.

### Discussion

There are many treatment options that can be carried out in Class II patients. In this case report, in both cases, extraction of the upper first premolars was an option in addition to non-extraction approach, however, it was decided to choose non-extraction treatment to avoid deterioration of the profile since the patient had tip up nose and average nasio-labial angle. In a comparative study, they found the nasio-labial angle became more obtuse in extraction group than non-extraction group.\*6 Forsus and SUS2 are effective in correcting Class II malocclusion. The most related skeletal changes occur in the maxilla by significant restraining the sagittal growth of the maxilla, while changes at the dentoalveolar level is highly significant in both arches.\*7 This comes in agreement with present cases, no significant change occurred in point A, and SNB angle increased about 3 degrees with a noticeable forward movement of the mandible after treatment and this could be due to residual growth of the mandible or may be related to the adaptive growth in the condyle. Another explanation could be the anterior repositioning of the mandible rather than forward growth. At the dentoalveolar level, the upper molars and incisors exhibited distal movement. The lower molars exhibited mesial movement and extrusion and the lower incisors proclined only 1 degree in case 1 (Forsus) while no changes occurred in case 2 (SUS2). There are many protocols suggested to limit the flaring of the lower incisors including the use of miniscrews anchorage as demonstrated in relevant study.\*8 However, in present study we used miniscrews anchorage only in case 2 (with SUS2) and we found no significant difference between two cases in terms of mandibular incisors proclination, similar findings reported by Eissa et al.\*9 Using negative root torque anterior bracket prescription (such as MBT), cinching lower arch wire distal to the last tooth and tight ligation of the arches on 0.019 × 0.025-inch SS (0.022 slot) was also suggested to overcome the unfavorable effect of lower incisors flaring.\*10 However, in present cases, Roth prescription used because it was the available brackets in the hospital and mandibular tooth anchorage was increased by applying other methods as described earlier. Buccal root torque could be applied to the lower incisors to limit the buccal inclination. The patients didn't show significant increase in the vertical skeletal relationship, this could be due to the mesial movement of the lower molars which cancelled the opening rotation of the mandible as suggested by Upadhyay et al.\*5 And this result in agreement with other authors.\*11 Patient comfort and problems related to the appliances such as breakages or ulcerations and their cost, which may influence the clinician's choice of appliance, are rarely considered in the literature. One year follow up of the patient (case 1) showed stable treatment results. Stability of early Class II treatment influenced by several factors including mandibular rotational growth patterns, airway obstructions, appliances manipulation, treatment timing, and retention. Long-term stability with functional appliances have been studied by few investigators, and most have reported favorable findings with prolonged retention.\*12 Stable results in present case (case 1) may be attributed to functional and stable interdigitation of teeth at the end of the treatment with favorable growth and good retention plan. Interincisal angle was 126.5° at the end of treatment and according to Berg it should not be over 140° after treatment to prevent overbite relapse and for long term stability.\*13 Similar stable results using Forsus FRD were reported by other authors.\*14 \*15

### Conclusion

- Forsus or SUS2 appliances can be used for early correction of Class II division 1 malocclusion and result in prominent dental and skeletal changes.
- The use of miniscrews anchorage have no significant effect in terms of limit or prevent mandibular incisors proclination.

- Results can be maintained by appropriate management and retention plan.

## References

1. Proffit WR, Fields HW, Moray LJ. Prevalence of malocclusion and orthodontic treatment need in the United States: estimates from the NHANES-III survey. *Int J Adult Orthod Orthognath Surg.* 1998;13:97–106.
2. McNamara JA Jr. Components of class II malocclusion in children 8-10 years of age. *Angle Orthod.* 1981 Jul;51(3):177-202. doi: 10.1043/0003-3219(1981)051<0177:COCIMI>2.0.CO;2. PMID: 7023290.
3. al-Emran S, Wisth PJ, Bøe OE. Prevalence of malocclusion and need for orthodontic treatment in Saudi Arabia. *Community Dent Oral Epidemiol.* 1990 Oct;18(5):253-5. doi: 10.1111/j.1600-0528.1990.tb00070.x. PMID: 2249408.
4. Jones G, Buschang PH, Kim KB, Oliver DR. Class II non-extraction patients treated with the Forsus Fatigue Resistant Device versus intermaxillary elastics. *Angle Orthod.* 2008 Mar;78(2): 332-8. doi: 10.2319/030607-115.1. PMID: 18251605.
5. Sabbagh Universal SUS2 (SUS2) : The effective Class II treatment [http://www.dentaurum.de/eng/orthodontic\\_2624.aspx](http://www.dentaurum.de/eng/orthodontic_2624.aspx). Accessed Mar. 5, 2008.
6. Upadhyay M, Yadav S, Nagaraj K, Uribe F, Nanda R. Mini-implants vs fixed functional appliances for treatment of young adult Class II female patients: a prospective clinical trial. *Angle Orthod.* 2012 Mar;82(2):294-303. doi: 10.2319/042811-302.1. Epub 2011 Aug 26. PMID: 21867432.
7. Franchi L, Alvetto L, Giuntini V, Masucci C, Defraia E, Baccetti T. Effectiveness of comprehensive fixed appliance treatment used with the Forsus Fatigue Resistant Device in Class II patients. *Angle Orthod.* 2011 Jul;81(4):678-83. doi: 10.2319/102710-629.1. Epub 2011 Feb 7. PMID: 21299410.
8. Aslan BI, Kucukkaraca E, Turkoz C, Dincer M. Treatment effects of the Forsus Fatigue Resistant Device used with miniscrew anchorage. *Angle Orthod.* 2014 Jan;84(1):76-87. doi:10.2319/032613-240.1. Epub 2013 Jun 17. Erratum in: *Angle Orthod.* 2014 Mar;84(2):383. PMID: 23772682.
9. Eissa O, El-Shennawy M, Gaballah S, El-Meehy G, El Bialy T. Treatment outcomes of Class II malocclusion cases treated with miniscrew-anchored Forsus Fatigue Resistant Device: A randomized controlled trial. *Angle Orthod.* 2017 Nov;87(6):824-833. doi: 10.2319/032717-214.1. Epub 2017 Sep 8. PMID: 28885034.
10. Zhang R, Bai Y, Li S. Use of Forsus fatigue-resistant device in a patient with Class I malocclusion and mandibular incisor agenesis. *Am J Orthod Dentofacial Orthop.* 2014 Jun;145(6): 817-27. doi: 10.1016/j.ajodo.2013.08.021. PMID: 24880853.
11. Giuntini V, Vangelisti A, Masucci C, Defraia E, McNamara JA Jr, Franchi L. Treatment effects produced by the Twin-block appliance vs the Forsus Fatigue Resistant Device in growing Class II patients. *Angle Orthod.* 2015 Sep;85(5):784-9. doi: 10.2319/090514-624.1. Epub 2015 Mar 18. Erratum in: *Angle Orthod.* 2016 Sep;86(5):877. PMID: 25786056.
12. Siara-Olds NJ, Pangrazio-Kulbersh V, Berger J, Bayirli B. Long-term dentoskeletal changes with the Bionator, Herbst, Twin Block, and MARA functional appliances. *Angle Orthod.* 2010 Jan; 80(1):18-29. doi: 10.2319/020109-11.1. PMID: 19852635.
13. Rolf Berg, Stability of deep overbite correction, *European Journal of Orthodontics*, Volume 5, Issue 1, February 1983, Pages 75–83
14. Zhang R, Bai Y, Li S. Use of Forsus fatigue-resistant device in a patient with Class I malocclusion and mandibular incisor agenesis. *Am J Orthod Dentofacial Orthop.* 2014 Jun;145(6): 817-27. doi: 10.1016/j.ajodo.2013.08.021. PMID: 24880853.
15. Atik E, Kocadereli I. Treatment of Class II Division 2 Malocclusion Using the Forsus Fatigue Resistance Device and 5-Year Follow-Up. *Case Rep Dent.* 2016;2016:3168312. doi: 10.1155/2016/3168312. Epub 2016 Feb 29. PMID: 27034855; PMCID: PMC4789427.