



Volume 7 Issue 6,
June 2021

Copyright

©2021 Mahendra Patait. This is an open access article distributed under the terms of the Creative Commons Attribution License, which permits unrestricted use, distribution, and reproduction in any medium, provided the original author and source are credited



Citation

Mahendra Patait (2021). Unveiling the perception of attractiveness using chimeric photographs *Int J Dent & Ora Hea*. 7:6, 15-19

ISSN 2471-657X

Published by
Biocore Group |
www.biocoreopen.org/ijdo/archive.php

International Journal of Dentistry and Oral Health

Case Report

Maxillary metastasis from lung adenocarcinoma as an initial manifestation: A rare case report with review of literature

Mahendra Patait¹, Shital Nikam², Saurabh mandalik³, Kedar Saraf⁴, Vishakha Choudhary⁵

¹ HOD Professor, Dept Of OMDR, SMBT Dental college

² Reader, Dept Of OMDR, SMBT Dental College and Hospital

³ PG student, Dept Of OMDR SMBT Dental College

⁴ Professor, Dept Of OMDR, SMBT Dental College

⁵ Pg Student, Dept Of OMDR, SMBT Dental college

Corresponding author: Mahendra Patait

Prof n Head Dept Of OMDR, SMBT Dental college, Sangamner, India.

E-mail: omdrhod@gmail.com

Article History: Received: June 04, 2021;

Accepted: June 14, 2021;

Published: June 19, 2021.

Abstract

Metastatic malignancies involving the jaws account for only 1% of all malignancies of the jaws. In 22% to 30% of cases, an oral presentation of metastasis is the first sign of the malignant disease. The malignant tumors that most commonly metastasize to the jaw bones in men are from the lung, prostate, kidney, bone, and adrenal gland. In women are from breast, adrenal gland, colorectal area, genital organs and thyroid gland. Metastatic involvement of the oral cavity is rare in lung cancer, but has significant consideration in the diagnosis and treatment. Metastasis of lung cancer to maxilla is extremely rare. We are reported a case of metastatic adenocarcinoma of the maxilla that was detected before the primary tumor of the lung. This case report highlights on clinical presentation of patient, investigations undertaken & also discussed review of literature.

Keywords

Lung adenocarcinoma, Maxillary metastasis.

Declaration of Conflicting Interest

The author[s] declared no potential conflicts of interest with respect to the research, authorship, and/or publication of this article.

Introduction

Distant metastasis of malignant tumors to the oral tissues is rare and account for 0.1% of all oral malignancies⁵. Clinical presentation of metastatic tumors is variable, which may create diagnostic dilemma or may lead to erroneous diagnosis. Metastatic tumors clinically may mimic as dental infections. Nearly 90% of metastatic tumors occur in jaw bones especially premolar-molar region of the mandible⁵. But maxillary metastasis is quite rare and unusual condition⁵. Approximately 70% of patients who were dying of cancer had evidence of metastatic disease⁵.

Lung cancers are one of the most common malignant lesions⁷ and are serious health problem for the whole world in terms of morbidity and mortality. There is a strong correlation between tobacco chewing, smoking and the development of lung cancer². Lung cancer can be present with visceral organ metastasis and/or bone metastasis at the time of diagnosis. It is known that metastasis are almost always from advanced lung cancer and such cases generally show a poor prognosis.¹

We reported a very rare case of maxillary metastasis which facilitated in locating primary malignancy of lung. This article emphasizes on importance of thorough oral examination and radiological investigation for diagnosis of such erratic lesion.

CASE REPORT

A 59-year-old male patient was reported to department of oral medicine and radiology with complaints of pain and swelling over right side of face since past 1 month. He had history of difficulty in swallowing and breathing since past one month and there is also a recent history of tooth extraction from maxillary 1st quadrant. The patient has habit of tobacco in both smoking and smokeless form since past 20 years, he smokes 10-15 bidis in a day and chews gutkha 4-5 times in a day.

Extraoral examination revealed (Figure 1) a diffuse swelling approximately 3.5cm X 3.5cm in size on the right side of the face. Swelling extended antero-posteriorly from the corner of the mouth to 3.5 cm front of the tragus of the ear and superio-inferiorly from outer canthus of the eye to approximately

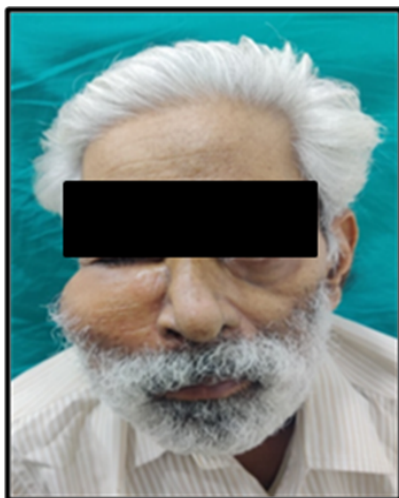

Figure - 1

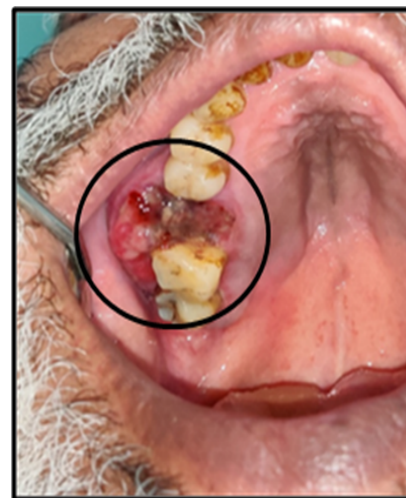

Figure - 2

3 cm above the lower border of mandible. The swelling was soft and tender on palpation and local temperature was not raised. A solitary lymph node of approximately 2cm x 1cm in size was palpable in a right submandibular region. The lymph node was firm, tender and fixed to surrounding structures on palpation. No other significant extra oral finding was noticed during the physical examination.

On intraoral examination (Figure 2), a roughly oval proliferative growth with ulcerations was noted in the right maxillary premolar- molar region. Lesion was approximately 1.5cm x 1.5cm in size with irregular ill defined margins. The color of the lesion was bright red with yellowish white pseudomembranous slough in some areas. The growth extended antero- posteriorly from distal aspect of 15 to distal aspect of 17, mediolaterally from buccal vestibule to palatal side of 15-17, supero-inferiorly from buccal vestibule to alveolar crest. On palpation growth was soft, tender, indurated and was fixed to underlying structure. Based on history and clinical examination investigation advised were OPG, CBCT, CT scan of neck and thorax, incisional biopsy of lesion.

OPG (Figure 3) revealed osteolytic radiolucent lesion in maxillary right alveolar area extending antero-posteriorly from distal aspect of 13 to distal aspect of 18 and supero-inferiorly from

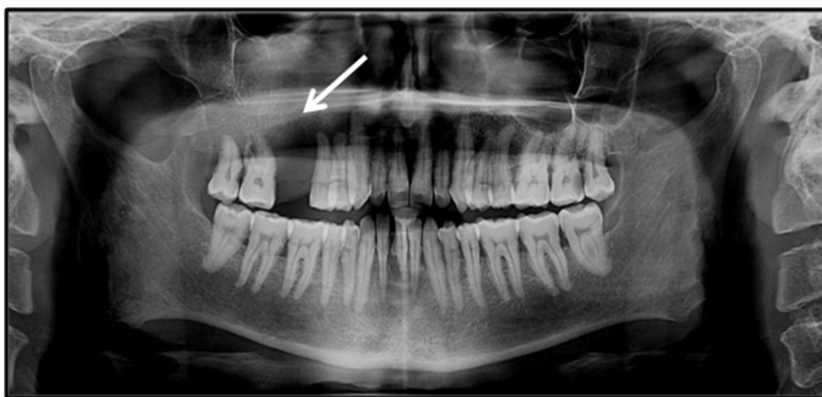

Figure - 3

maxillary sinus to crest of alveolar bone. Loss of lamina dura was seen with 14, 15, 17, 18. Right maxillary sinus appears hazy compared to left maxillary sinus along with breach in continuity of floor of maxillary sinus, suggestive of involvement of right maxillary sinus by lesion.

Cone Beam Computed Tomography (CBCT) scan images (axial section (figure 4), sagittal section (figure 5), the coronal section (figure 6) and 3d reconstructed view (figure 7) showed an ill-defined radiolucent osteolytic lesion in right maxillary posterior region extending mediolaterally from lateral wall of nasal bone to the lateral wall of maxillary sinus, superior-inferiorly involving 2/3rd of maxillary sinus to alveolar crest and antero-posteriorly from distal 13 to the maxillary tuberosity region. Approx. size of lesion was about 3.8 x 3.6 x 3.5 cm. Destruction of floor, anterior wall of right maxillary sinus was noted, along with involvement of surrounding structures like lateral wall of nose & palate was observed. 2/3rd of right maxillary sinus appeared radiopaque suggestive of lesion infiltrating into sinus cavity.

CT scan of Neck and Thorax revealed enlarged ipsilateral level II lymph node on right side with size of the largest node was around 12x6mm. Level II lymph node appeared to be reactive. Also, few enlarged nodes were seen in tracheoesophageal groove, largest on left side abutting and causing bulge in the wall of the esophagus- measuring 1.3x1cm- appeared suspicious for metastatic node. Few subcm sized nodules were seen in the right lung, larger measuring 5 X 5 mm, which were too small to characterize.

Incisional biopsy was done and histopathological examination showed poorly differentiated tumour cells with mucinous differentiation and extensive ulceration. The cells are arranged in glandular pattern. The surrounding stroma is cellular. The pattern suggested metastatic adenocarcinoma from

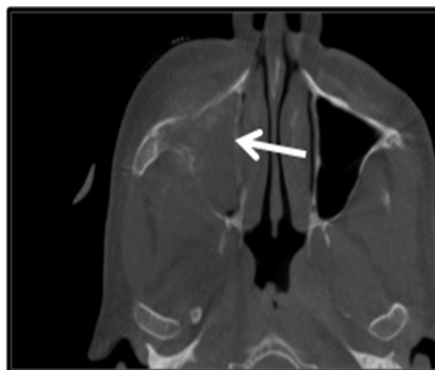


Figure - 4

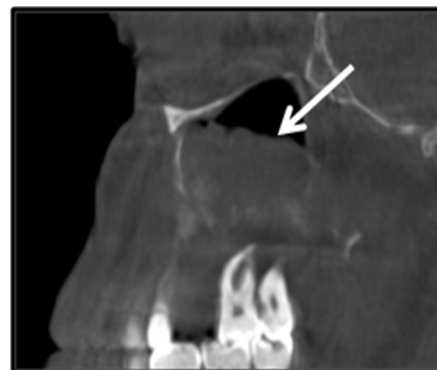


Figure - 5

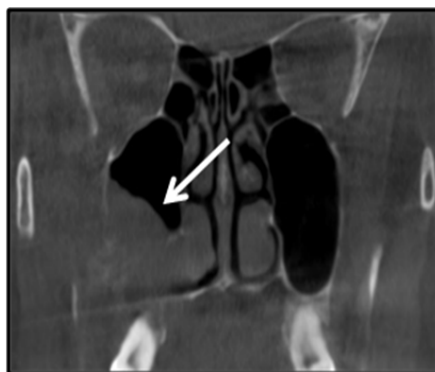

Figure - 6

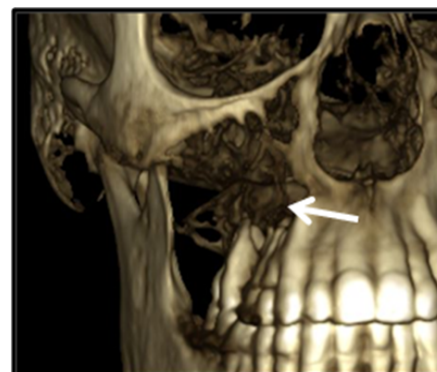


Figure - 7

the lung.

On the clinical radiological and histopathological examination the final diagnosis of the lesion was Adenocarcinoma of lung metastasis in maxilla on right side.

Discussion

Metastasis is a biological complex process that involves detachment from the surrounding cells, regulation of cell motility, invasion, survival, proliferation, and evasion of the immune system⁵. Metastasis to the soft tissues mostly involves gingiva (54%) followed by alveolar mucosa (50%) and tongue (30%)⁵.

Lung cancer is characterized by subtle onset, complexity of identification early metastatic spread, and direct prognostic implications. Lung cancers are one of the most common malignant lesions, among them bronchogenic carcinoma of the lung is one of the leading causes of mortality².

Bronchogenic carcinoma has a predilection for middle aged men. Robbins states that at the present time cigarette smoking is the most important causative agent. There is a strong correlation between tobacco chewing, smoking and the development of lung cancer². Bronchogenic carcinomas, which comprise approximately 90% of lung cancers, are broken down into the following categories: Squamous cell carcinoma, Adenocarcinoma, Large cell carcinoma, and Oat cell carcinoma. These categories are not always distinct, since a certain amount of "blending" occurs between these different forms⁴.

Metastatic involvement of the oral cavity is an infrequent but important consideration in the diagnosis and treatment of malignant lesions of the lung. The oral cavity, because of its ease of examination, occasionally exhibits confirmation of metastatic disease before the primary lesion is apparent.

George E. et al surveyed a literature on lung malignancies metastatic to the oral cavity; they present the following conclusion regarding intraoral metastasis of bronchogenic carcinoma⁴:

1. The average age at incidence was 54.0 years.
2. There was a predominant male predilection (34 males: 4 females).
3. A significant number of cases (48.6%) revealed that the intraoral metastasis receded discovery of the primary tumor.
4. The mandible was the most favored site-21/38 cases (55.2%).
5. Symptoms were quite variable and infrequent.

Malignant tumors reported to have metastasized to the jaws include bronchogenic carcinoma, angiosarcoma, transitional cell carcinoma, neuroblastoma, breast carcinoma, medulloblastoma, seminoma, prostate carcinoma, follicular thyroid carcinoma, osteosarcoma, hepatocellular carcinoma, Ewing's sarcoma, and signet-ring cell adenocarcinoma¹¹

A review of literature by Kent and Majumdar noted that renal carcinoma is the most common metastatic tumor to the maxilla¹¹. So the metastasis from lung to the maxilla is a rare incident.

The medical literature since 1964 has reported only 17 cases of gingival metastasis from the lung with a complete histologic identification of a primary lung cancer; of these only 4 cases were adenocarcinoma. Out of these, all the 17 patients were male. Median age of occurrence was 58 years and age ranged from 48-84 years²

The metastasis to paranasal sinus from lung cancer has rarely been reported in Japan. In 2008, Sakai reported that paranasal sinus metastasis from lung cancer was exceedingly rare, with only 4 cases in Japan, and tended to occur in males¹

Joel M Bernstein et al conducted a study on metastatic tumors to the maxilla nose and paranasal sinuses. The study concluded that the metastasis to the maxillary sinus, ethmoid sinus, frontal sinus and nasal cavity were found in decreasing order while the sphenoid sinus, nasopharynx, hard palate and alveolar ridge were less commonly involved¹²

In the case series of Prescher and Brors 169 patients were involved, where only 33% of maxillary sinus metastasis was observed and the metastasis was originated from lung in 9% of all patients¹⁴.

Metastasis is the termination of a multistage process in which malignant tumor cells detach themselves from the primary tumor and then move into vascular and lymphatic vessels until they have become lodged in the capillary bed. Subsequently, they begin to penetrate the blood vessel walls, invade the surrounding tissue and proceed to proliferate. It is convincing that circulating tumor cells become entrapped in a rich capillary network of chronically inflamed gingiva²; whereas malignancies that spread via the lymphatic system are generally limited to primary sites near the jaws¹¹

While pathogenesis of distant metastatic tumor to paranasal sinus was discussed by Nahum and Bailey, they emphasized on the role of the Batson's plexus, a prevertebral venous network without valves, which authorizes the retrograde crossing of tumour cells from the lungs towards the face^{2, 12}

George E. et al published a study of lung malignancies metastatic to the oral cavity, they determine Relationship of dental trauma to incidence of oral metastasis this would support a "seeding" hypothesis where it is thought that cells from the lungs settle out in areas of trauma via the sputum. It is appealing to consider that the traumatized areas of dental extractions might have provided the milieu for the proliferation of sputum borne cancer cells⁴

Clinically, the gingival metastatic tumors closely resemble and are easily mistaken for benign reactive lesions or neoplasm, such as lobular capillary hemangiomas. Besides the rarity of this particular case, its presenting symptoms, which mimicked those of localized inflammatory periodontal disease, which is a common feature of malignant diseases of jaw¹⁰

Radiographically, the malignant lesion shows "teeth float in air," with irregular lesional margins. The malignant process may create root resorption with an irregular margin or a "spiked" root. If the metastasis progresses, pathologic fracture of the mandibular or alveolar process is possible.

Miyahara described that surgical resection for metastatic tumors in the paranasal sinus were important for alleviating the symptoms. The minimally invasive surgery could improve the quality of life by relieving the nasal pain until the cancer recurred¹.

Malignancy must be suspected if any of the following signs are present²:

1. A fast evolution

2. A hemorrhagic tendency
3. Mechanical disorders caused by the development of the tumor
4. An ulcerated and/or necrotic aspect
5. General clinical context of the patient

Conclusion

As the maxillary metastasis from lung carcinoma is rare, diagnosis of metastatic lesions in the oral region is challenging both to the clinician and to the pathologist. Thorough examination of the patient and biopsy of the existing lesion should be carried out for definitive diagnosis. The average survival rate for lung cancer metastasis is 4-month to 1-year with a maximum survival rate of five years. Early detection of metastasis and appropriate treatment are necessary to improve the quality of life.

References

- [1] Kusunoki T, Homma H, Kidokoro Y, Yanai A, Ikeda K, Wada R. A case of maxillary bone metastasis from lung cancer. *Clinics and practice*. 2015 Nov 5;5(4).
- [2] Prakash SR, Verma S, Gill N, Malik V. Multiple gingival metastasis of adenocarcinoma of the lung. *Indian Journal of Dental Research*. 2012 Jul 1;23(4):558.
- [3] Zachariades N. Neoplasms metastatic to the mouth, jaws and surrounding tissues. *Journal of Cranio-Maxillofacial Surgery*. 1989 Aug 1;17(6):283-90.
- [4] Kaugars GE, Svirsky JA. Lung malignancies metastatic to the oral cavity. *Oral Surgery, Oral Medicine, Oral Pathology*. 1981 Feb 1;51(2):179-86.
- [5] Kanth MR, Prakash AR, Reddy YR, Bai JS, Babu MR. Metastasis of lung adenocarcinoma to the gingiva: A rare case report. *Iranian journal of medical sciences*. 2015 May;40(3):287.
- [6] Ellis GL, Jensen JL, Reingold IM, Barr RJ. Malignant neoplasms metastatic to gingivae. *Oral Surgery, Oral Medicine, Oral Pathology and Oral Radiology*. 1977 Aug 1;44(2):238-45.
- [7] Gulmez A, Gulbas H, Ozcan M and Elkiran ET A rare case: Lung cancer with maxillary metastasis 2020 3: 1-3
- [8] Sawheny E, Jones K, Keddissi J, Kinasewitz G. Metastatic Lung Carcinoma Involving the Maxillary Gingiva. *Chest*. 2011 Oct 1;140(4_MeetingAbstracts).
- [9] Milobsky SA, Milobsky L, Epstein LI. Metastatic renal adenocarcinoma presenting as periapical pathosis in the maxilla. *Oral Surgery, Oral Medicine, Oral Pathology and Oral Radiology*. 1975 Jan 1;39(1):30-3.
- [10] Tideman H, Arvier JF, Bosanquet AG, Wilson DF. Esophageal adenocarcinoma metastatic to the maxilla. *Oral surgery, oral medicine, oral pathology*. 1986 Nov 1;62(5):564-8.
- [11] Willard CC, Weber CR, Buche W. Metastatic esophageal adenocarcinoma involving the maxilla. *Journal of oral and maxillofacial surgery*. 2002 Dec 1;60(12):1496-9.
- [12] Bernstein JM, Montgomer WW, Balogh Jr K. Metastatic tumors to the maxilla, nose, and paranasal sinuses. *The laryngoscope*. 1966 Apr;76(4):621-50.
- [13] Kim GE, Park HC, Keum KC, Lee CG, Suh CO, Hur WJ, Kim KM, Hong WP. Adenoid cystic carcinoma of the maxillary antrum. *American journal of otolaryngology*. 1999 Mar 1;20(2):77-84.
- [14] Ates, O. Yazici, H. Ates, N. Ozdemir, N. Zengin Unusual metastasis of lung cancer : Bulbous oculi and maxillary sinus. *Experimental oncology* 2015 37, 3,231-232