



## Thymic Carcinoma Metastatic to the Mandible Mistaken for Medication- Related Osteonecrosis of the Jaw: A Case Report and Review of the Literature

Cameron Y. S. Lee<sup>1</sup>, Mobeen Rahman<sup>2</sup>, Kristin L. Lee<sup>3</sup>, Kirk Y. Hirata<sup>4</sup>

<sup>1</sup>Private Practice in Oral, Maxillofacial and Reconstructive Surgery, Aiea, Hawaii USA Clinical Professor of Surgery, Department Of Periodontology and Oral Implantology Kornberg School Of Dentistry, Temple University, Philadelphia, Pa 19140, USA

<sup>2</sup>Pathology Resident, John A. Burns School of Medicine, University of Hawaii, Honolulu, Hawaii, 96813, USA

<sup>3</sup>First Year Oral and Maxillofacial Surgery Resident, Highland Hospital, Department of Oral and Maxillofacial Surgery, Oakland, CA, 94602, USA

<sup>4</sup>Staff Pathologist, The Queen's Medical Center, Honolulu, Hi Associate Clinical Professor of Pathology, John A. Burns School of Medicine University of Hawaii, Honolulu, Hawaii 96813, USA

### Abstract

Thymic tumors usually metastasize locally to the liver, lung, bone and brain. Thymic carcinoma metastasizing to the mandible is a rare occurrence. This case report describes metastatic thymic carcinoma that was presumed to be medication-related osteonecrosis of the jaw after extraction of a molar tooth. To our knowledge, there have been no reported cases of metastases from the thymus gland to the mandible in the medical and dental English literature. We report a case of metastatic thymic carcinoma to the mandible that was mistaken for medication-related osteonecrosis of the jaw (MRONJ)

**Keywords:** Thymic carcinoma Rare, Extrathoracic metastasis, Medication-related osteonecrosis of the mandible (MRONJ)

### Corresponding author: Cameron Y. S. Lee

Private Practice in Oral, Maxillofacial and Reconstructive Surgery, Aiea, Hawaii USA Clinical Professor of Surgery, Department Of Periodontology and Oral Implantology Kornberg School Of Dentistry, Temple University, Philadelphia, Pa 19140, USA. Tel: 808-484-2288, Fax: 808-484-1181, E-mail: [clees55294@aol.com](mailto:clees55294@aol.com)

**Citation:** Cameron Y. S. Lee et al. (2018), Thymic Carcinoma Metastatic to the Mandible Mistaken for Medication- Related Osteonecrosis of the Jaw: A Case Report and Review of the Literature. *Int J Dent & Oral Heal.* 4:9, 136-141

**Copyright:** ©2018 Cameron Y. S. Lee et al. This is an open-access article distributed under the terms of the Creative Commons Attribution License, which permits unrestricted use, distribution, and reproduction in any medium, provided the original author and source are credited

**Received:** August 15, 2018

**Accepted:** August 21, 2018

**Published:** September 27, 2018

### Introduction

Metastatic carcinoma of the jaws represents 1% of all malignancies of the oral cavity<sup>[1,2,3]</sup> The mandible is the primary anatomic site of metastases.<sup>[4]</sup> In women, metastases has been reported to occur from distant sites such as the breasts, kidneys, genitals, colorectal region and thyroid gland. In men, they can metastasize from the lungs, kidneys, prostate gland, and colorectal region.<sup>[15,6,7,8]</sup> Metastasis via vascular dissemination from abdominal organs to the oral and maxillofacial region is considered rare because malignant cells must

circulate through organs such as the lung and liver<sup>[9]</sup>. To the best of our knowledge, there have been no reported cases of extrathoracic metastases from the thymus gland to the mandible. We present a case of metastatic thymic carcinoma to the mandible that was mistaken for medication-related osteonecrosis of the jaw (MRONJ).

Thymic neoplasms are rare tumors of the anterior mediastinum with an incidence estimated at 1 to 3 cases per 10 million individuals.<sup>[10,11]</sup> Thymic carcinoma is usually diagnosed during the fifth to seventh decade of life. Although most metastatic sites were not biopsied and histology not available, Ichino et al.<sup>[12]</sup> was able to document 83 cases of extrathoracic metastasis from the thymus gland. In a more recent study, Huang and colleagues<sup>[13]</sup> described 120 cases of thymic tumors treated at Memorial-Sloan Kettering Cancer Center from 1995 to 2006. Of the 120 patients, eight developed extrathoracic metastatic thymic carcinoma. As in the previous study, this was not confirmed histologically, as all 8 patients did not complete biopsy procedures. However, in review of thirty-five cases of extrathoracic metastasis of thymus origin, liver and lymph node were the most frequent metastatic sites and 9 cases were biopsy positive for lymph node metastasis<sup>[14]</sup>.

Thymic tumors are derived from thymic epithelium of the thymus gland, which is important in childhood immunity. In adults, the gland is still present, but in an atrophic state<sup>[15,16]</sup>. It is the most common tumor of the anterior mediastinum in adults.<sup>[14,17]</sup> Patients with thymic carcinoma may have any of the following clinical symptoms: chest pain, back pain, dyspnea, voice changes, cough, dysphagia, fatigue and weight loss.<sup>[18]</sup> Rarely, polymyositis or dermatomyositis are observed in the patient with thymic carcinoma.<sup>[19,20,21]</sup> There are two types of tumors derived from the thymus gland, thymomas and thymic carcinoma. Thymomas make up about 50% of tumors of the anterior mediastinum. Thymic carcinoma is a rare malignancy and accounts for 5% of all malignancies of thymic origin. Compared to thymoma,

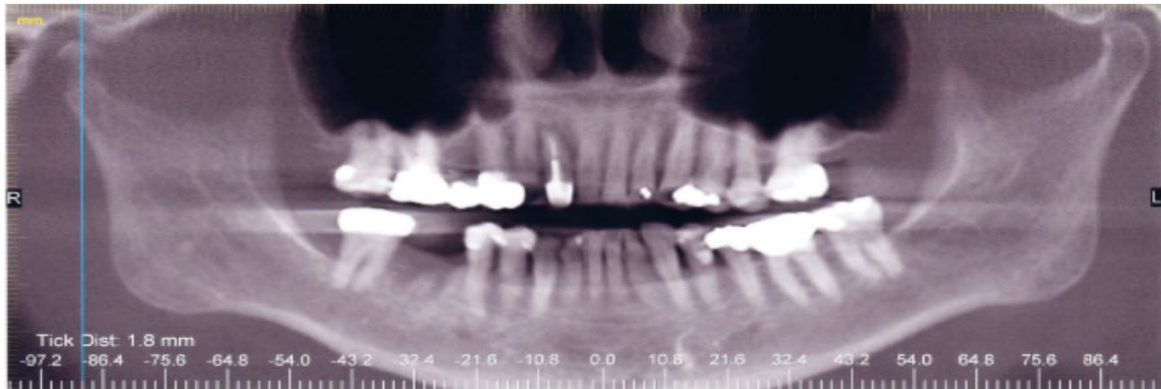
Citation: Cameron Y. S. Lee et al. (2018), Thymic Carcinoma Metastatic to the Mandible Mistaken for Medication- Related Osteonecrosis of the Jaw: A Case Report and Review of the Literature. *Int J Dent & Oral Heal.* 4:9, 136-141

thymic carcinoma has a greater metastatic potential and invasiveness that results in a poor prognosis.<sup>[22,23,24,25]</sup> Of the 11 different subtypes recognized by the 2004 World Health Organization classification, squamous cell carcinoma is the most common subtype and accounts for up to 40% of reported cases. Histologically, it is undistinguishable from carcinoma from other organs.<sup>[22,26,27,28]</sup>

### Case Report

In January 2017, a 74-year old Asian female was referred from her dentist for a non-healing extraction site. A molar tooth of the right posterior mandible was extracted in October 2016 due to mobility and pain. One month after the tooth extraction, the dentist performed a

local curettage for a post-operative infection. As the infection failed to resolve and was unresponsive to antibiotic therapy, the family dentist was concerned about the possibility of medication-related osteonecrosis of the jaw. The patient was treated for osteoporosis for greater than 5 years with the bisphosphonate drug, fosamax (70mg/week) for osteoporosis. At the time of clinical presentation, the patient was also diagnosed with stage IVb thymic carcinoma (Masaoka staging system) and treated with combination systemic chemotherapy consisting of carboplatin (300mg/m<sup>2</sup>/day) and paclitaxel (200mg/m<sup>2</sup>/day) every three weeks. Panoramic radiograph revealed a mixed radiolucent-radiopacity in the area of the extraction site (Figure 1).



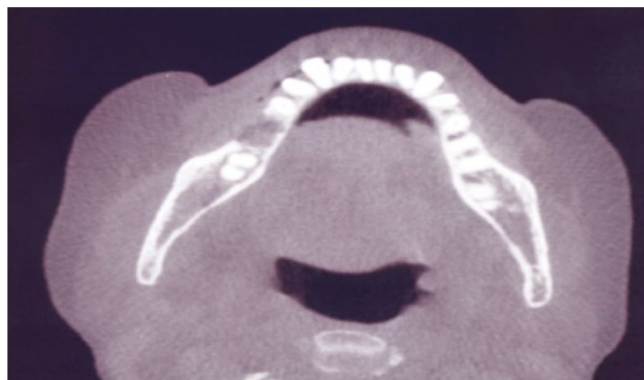
**Figure 1.** Panoramic radiograph showing osteolytic lesion with ill-defined margins and what appears to be bone fragments in the right posterior mandible.

The patient reported that there was a constant aching pain in the right posterior mandible that failed to resolve by both narcotic and non-steroidal over the counter medications after the molar tooth was extracted by her dentist. She also reported a history of paresthesia over the skin of the right chin and right lower lip. Based on the patient's medical history and clinical findings, metastatic disease to the mandible could not be excluded. The differential diagnosis included medication-related osteonecrosis of the mandible, osteomyelitis and thymic carcinoma metastatic to the mandible.

The patient's medical history was significant for osteoporosis, hyperlipidemia, depression and stage IVb thymic carcinoma diagnosed in January 2015 by supraclavicular lymph node biopsy. At the time of presentation, the anterior mediastinal tumor was inoperable. No

allergies to medication were reported by the patient. She was a former smoker for 20 years who quit in 1980. Physical examination revealed a female in mild distress from the chronic, unrelenting pain in the right mandible. No facial swelling, asymmetry or orocutaneous fistula was observed. Cranial nerve examination revealed a V<sub>3</sub> paresthesia over the skin of the right chin and right lower lip. Head and neck examination was positive for lymphadenopathy.

Oral examination of the right posterior mandible revealed teeth #30 and 32 missing. The gingival tissues in the area of missing tooth #30 were edematous and erythematous with signs of inflammation. Purulent discharge was observed from the non-healing extraction site. No exposed bone was observed in the extraction site. Cone beam CT scan revealed an osteolytic lesion with destruction of the buccal cortical plate of the right posterior mandible (Figure 2).



**Figure 2:** Axial cone beam CT scan reveals osteolytic lesion with erosion of the buccal cortex of the right posterior mandible.

Under local anesthesia, the extraction site was debrided of non-vital necrotic osseous and granulation tissue under local anesthesia. The tissue specimens were sent to the laboratory for histopathologic examination.

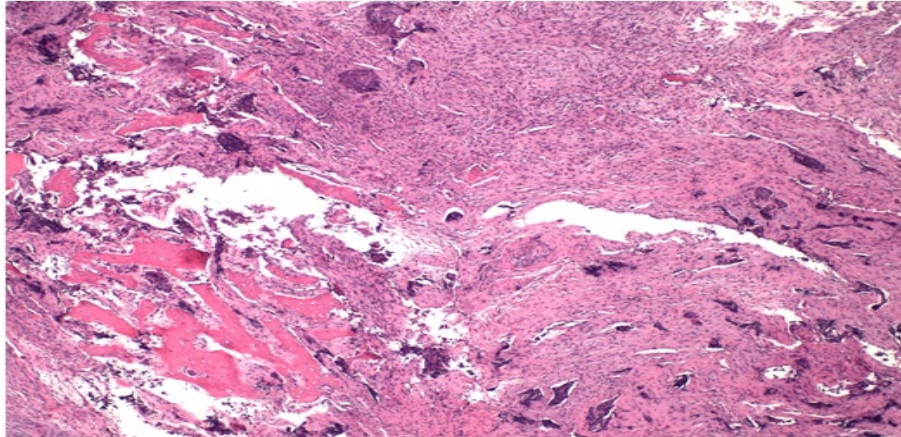
### Histopathology

Decalcified sections of bone from the right posterior mandible revealed devitalized bone infiltrated by nests of neoplastic cells associated with a desmoplastic response. Tumor cells demonstrated

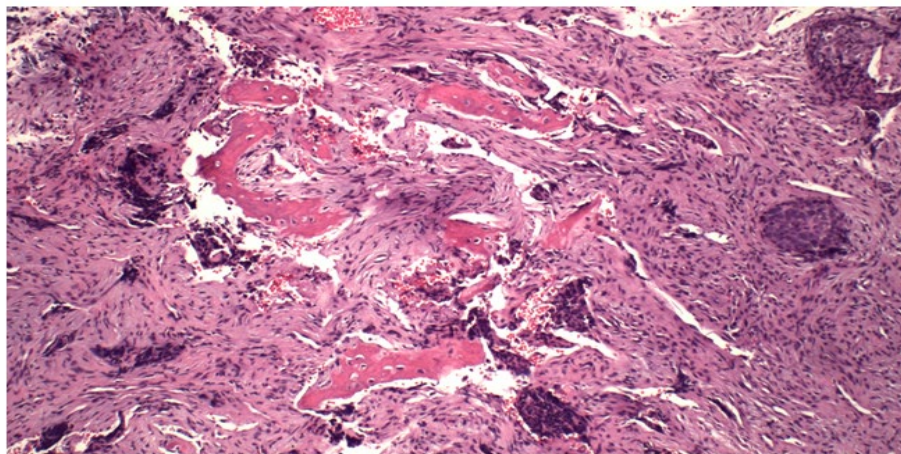
atypical enlarged nuclei with prominent nucleoli. Occasional mitotic figures were observed. (Figure 3A and 3B). The results are consistent with squamous cell carcinoma of the mandible and are similar to a supraclavicular lymph node biopsy performed at another medical center.

### Immunohistochemistry

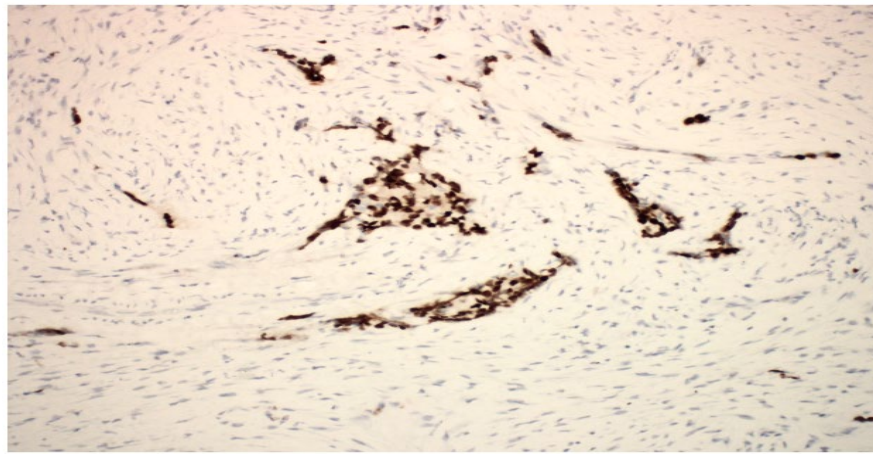
Immunohistochemical analysis revealed that the neoplastic cells stained immunopositive for p40 (Figure 4A) and CD5 (Figure 4B).



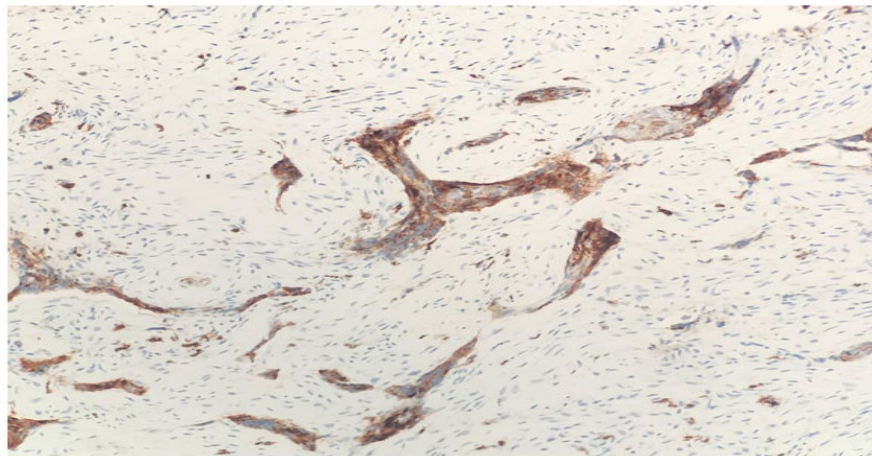
**Figure 3A:** Histopathologic analysis of specimen from right mandible (hematoxylin and eosin stain). Lower power view (original magnification x 10) shows infiltration of large islands of polygonal neoplastic cells of varying size.



**Figure 3B:** High power view (original magnification x 20) shows bone infiltrated by neoplastic epithelial cells with enlarged nuclei, marked pleomorphism, eosinophilic glassy cytoplasm and hyperchromasia.



**Figure 4A:** Immunohistochemical analysis of specimen from right mandible. Neoplastic cells are positive for p40 and CD5 suggestive of squamous cell thymic carcinoma metastatic to the mandible.



**Figure 4B:** Immunohistochemical analysis of specimen from right mandible. Neoplastic cells are positive for p40 and CD5 suggestive of squamous cell thymic carcinoma metastatic to the mandible.

## Discussion

Bisphosphonates are the cornerstone in the management of osteoporosis and prevention of skeletal related events.<sup>[29,30,31]</sup> Patients prescribed bisphosphonates who complete surgery that involves the jaw bones are at risk for developing MRONJ. They may experience delayed wound healing that results in dehiscence of soft tissues with exposed necrotic bone, pain, infections involving both hard and soft tissues of the affected area and altered neurosensation.<sup>[32,33,34,35]</sup> There have also been reports of patients treated with the cancer medications carboplatin and paclitaxel that may develop MRONJ. Wang et. al.<sup>[36]</sup> reported three cases of osteonecrosis of the jaw associated with systemic cancer chemotherapy for metastatic breast cancer. The risk of developing osteonecrosis of the jaws is approximately 1% for patients treated with both drugs.<sup>[37,38]</sup> Paclitaxel is an antimicrotubulin agent that binds to microtubules during mitosis and prevents cell division in malignant and normal cells.<sup>[39]</sup> Such antitumor effect at the cellular level may lead to osteonecrosis. Carboplatin is a derivative of the chemotherapy cancer alkylating agent, cisplatin.<sup>[37,40]</sup> It binds

to DNA and inhibits synthesis by cross-linking the DNA strands. Such action results in cell death. Cancer polychemotherapy is the standard of care, as both drugs have their primary effect at different phases of the reproductive cell cycle. Because metastatic lesions to the oral cavity are rare and may be mistaken for MRONJ, they can pose a diagnostic challenge.<sup>[41, 42, 43]</sup> Bedogni and colleagues<sup>[44]</sup> reported two cases that were mistaken for MRONJ based on medical history, clinical and radiographic findings. In both cases, biopsy of the jaw was not performed and the patients underwent surgical resection of the jaw because of failure to resolve the osteonecrosis with antibiotic treatment and constant pain. In our case, thymic carcinoma metastatic to the mandible was also a diagnostic challenge as the clinical and radiographic signs and symptoms were not pathognomonic for MRONJ. Therefore, the authors recommend that incisional biopsy for histopathologic analysis be routinely performed in patients with documented malignancy.<sup>[1,41-44,47]</sup>

Based on the medical history of stage IVb thymic carcinoma, no exposed bone observed and that our patient was experiencing paresthesia of the right lower lip and chin, metastatic disease was an important consideration in the differential diagnosis even though she was referred by her dentist for suspected MRONJ. Altered neurosensory function involving the chin and lower lip is considered a major clinical symptom of metastatic disease to the oral cavity.<sup>[48,49,50]</sup> Clinical signs and symptoms of metastatic lesions of the oral cavity are similar to MRONJ and may include edema, erythema, pain, mobility of teeth, soft tissue masses, pathologic fractures and altered neurosensation.<sup>[1,6,51,52,53]</sup>

The clinician must always be aware that MRONJ and metastatic lesions to the oral cavity have many similar pathognomonic radiographic signs.<sup>[41,42,44,47]</sup> In an analysis of 390 cases, Hirshberg et al<sup>[54]</sup> discovered that 5.4% did not demonstrate any radiographic changes suggestive of metastatic disease to the jaws. In a retrospective study of 114 metastatic tumors in the jaws, D'Silva and colleagues<sup>[7]</sup> reported that no radiographic evidence was detected in 5% of the cases studied. However, intraosseous carcinoma on computed tomography may appear as a homogenous mass with irregular borders and bone destruction.<sup>[55]</sup>

Although treatment of thymic carcinoma is beyond the scope of this case report, it is important to realize that the prognosis of metastatic lesions to the oral cavity usually have a poor prognosis.<sup>[56]</sup> In a Japanese study, 46.5% of patients with stage IVb thymic carcinoma have more advanced disease at the time of presentation and therefore, are unresectable compared to patients that are diagnosed with stage IV thymoma.<sup>[57]</sup> Such poor prognosis is usually due to a delay in the initial diagnosis.<sup>[2,3,25,57]</sup> The 5-year survival rate is less than 10%.<sup>[25,58,59]</sup> At the time of presentation, our patient had already been diagnosed at an advanced tumor stage with metastases to the liver and skeleton. The patient expired five months later after the biopsy procedure of the mandible.

In the evaluation of the patient with metastatic thymic disease, it is important to rule-out other neoplasms.<sup>[46,60]</sup> The differential diagnosis of metastatic squamous cell thymic carcinoma to the jaw should include metastasis from other mediastinal organs such as the lung and esophagus. Because there is no current immunohistochemical marker for thymic carcinoma and the morphologic variation of this neoplasm, exclusion of metastatic disease from the thymus gland must rely on clinical and imaging studies, and examination of biopsy samples when available. For the patient with an anterior mediastinal mass, clinical symptoms described earlier and no tumor discovered in another part of the patient, thymic carcinoma must be included in the differential diagnosis.<sup>[14]</sup>

## Conclusion

This case report emphasizes the importance of obtaining a careful medical history in addition to a thorough clinical examination. This is especially with the patient that presents with presumed medication-related osteonecrosis of the jaws but has a significant medical history of metastatic disease. Imaging studies such as plain radiographs and computed tomography are not specific for either MRONJ or metastasis to the jaws. For a definitive diagnosis for either pathologic entity, we recommend routine incisional biopsy for histopathologic examination of all patients with metastatic disease.

## References

1. Meyer I, Shklar G. [Malignant tumors metastatic to mouth and jaws](#). *Oral Surg Oral Med Oral Pathol*. 1965; 20: 350-362.
2. Hirshberg A, Leibovich P, Buchner A. [Metastatic tumors to the jawbones: analysis of 390 cases](#). *J Oral Pathol Med*. 1994; 23: 337-341.

3. van der Waal RI, Butler J, van der Waal I. [Oral metastases: report of 24 cases](#). *Br J Oral Maxillofac Surg*. 2003; 41: 3-6.
4. Glaser C, Lang S, Pruckmayer M, et al. [Clinical manifestations and diagnostic approach to metastatic cancer of the mandible](#). *Int J Oral Maxillofac Surg*. 1997; 26: 365-
5. Nishimura Y, Yakata H, Kawasaki T, et al. [Metastatic tumours of the mouth and jaws. A review of the Japanese literature](#). *J Maxillofac Surg*. 1982; 10: 253-258.
6. Zachariades N, Koumoura F, Vairaktaris E, et al. [Metastatic tumours to the jaws. A report of seven cases](#). *J Oral Maxillofac Surg*. 1989; 47: 991-996.
7. D'Silva NJ, Summerlin DJ, Cordell KG, et al. [Metastatic tumors in the jaws: a retrospective study of 114 cases](#). *J Am Dent Assoc*. 2006; 137: 1667-1672.
8. Friedrich RE, Abadi M. [Distant metastases and malignant cellular neoplasms encountered in the oral and maxillofacial region: analysis of 92 patients treated at a single institution](#). *Anticancer Res*. 2010; 30: 1843-1848.
9. Imamura S, Suzuki H. [Head and neck metastases from occult abdominal primary site: a case report and literature review](#). *Acta Otolaryngol*. 2004; 124: 107-112.
10. Okumura M, Miyoshi S, Fujii Y, et al. [Clinical and functional significance of WHO classification on human thymic epithelial neoplasms: a study of 146 consecutive tumors](#). *Am J Surg Pathol*. 2001; 25: 103-110.
11. Engels EA, Pfeiffer RM. [Malignant thymoma in the United States: demographic patterns in incidence and associations with subsequent malignancies](#). *Int J Cancer*. 2003; 105: 546-551.
12. Ichino Y, Obuchi M, Suko K, et al. [Malignant thymoma with distant metastases: a case report and review of the literature](#). *Jpn J Clin Oncol*. 1983; 13: 733-739.
13. Huang J, Rizk NP, Travis WD, et al. [Comparison of patterns of relapse in thymic carcinoma and thymoma](#). *J Thorac Cardiovasc Surg*. 2009; 138: 26-31.
14. Vladislav T, Jain RK, Alvarez R, et al. [Extrathoracic metastases of thymic origin: a review of 35 cases](#). *Modern Pathology*. 2012; 25: 370-377.
15. Miller JF. [Thymus and immunity-II. The last three decades](#). *Eur J Cancer Clin Oncol*. 1988; 24: 1257-1262.
16. Thomas CR. [Thymoma: state of the art](#). *J Clin Oncol*. 1999; 17: 2280-
17. Schmidt-Wolf IG, Rockstroh JK, Schuller H, et al. [Malignant thymoma: current status of classification and multimodality treatment](#). *Ann Hematol*. 2003; 82: 69-76.
18. Moran CA, Suster S. [Thymic carcinoma: current concepts and histologic features](#). *Hematol Oncol Clin N Am*. 2008; 22: 393-407.
19. Inoue Y, True LD, Martins RG. [Thymic carcinoma associated with paraneoplastic polymyositis](#). *J Clin Oncol*. 2009; 27: e33-34.
20. Azuma Y, Shiga K, Ishii R, et al. [Polymyositis with atypical pathological features associated with thymic carcinoma](#). *Intern Med*. 2009; 48: 163-168.
21. Takahashi F, Tsuta K, Nagaoka T, et al. [Successful resection of dermatomyositis associated with thymic carcinoma: report of a case](#). *Surg Today*. 2008; 38: 245-248.
22. Suster S, Rosai J. [Thymic carcinoma: a clinicopathologic study of 60 cases](#). *Cancer*. 1991; 67: 1025-1032.
23. Eng TY, Fuller CD, Jagirdar J, et al. [Thymic carcinoma: state of the art review](#). *Int J Radiat Oncol Biol Phys*. 2004; 59: 654-664.
24. Engels EA. [Epidemiology of thymoma and associated malignancies](#). *J Thorac Oncol*. 2010; 4 (suppl 4(10)): S260-S265.

25. Scorsetti M, Leo F, Trama A, et al. [Thymoma and thymic carcinomas. Critical Reviews in Oncology/Hematology.](#) 2016; 99: 332-350.
26. Kuo TT, Chang JP, Lin FJ, et al. [Thymic carcinomas: histopathological varieties and immunohistochemical study.](#) *Am J Surg Pathol.* 1990; 14: 24-24.
27. Hsu CP, Chen CY, Chen CL, et al. [Thymic carcinoma. Ten years' experience in twenty patients.](#) *J Thorac Cardiovasc Surg.* 1994; 107: 615-620.
28. Weissfeldt A, Moran CA. [Thymic carcinoma, part 1. A clinicopathologic and immunohistochemical study of 65 cases.](#) *Am J Clin Pathol.* 2012; 188: 103-114.
29. Rosen CJ. Postmenopausal osteoporosis. *N Engl J Med.* 2005; 353: 595-603.
30. Khosla S. [Increasing options for the treatment of osteoporosis. Editorial.](#) *N Engl J Med.* 2009; 361: 818-820.
31. Favus MJ. [Bisphosphonates for osteoporosis.](#) *N Engl J Med.* 2010; 363: 2027-2035.
32. Marx RE. [Pamidronate \(Aredia\) and zoledronate \(Zometa\) induced avascular necrosis of the jaws: A growing epidemic.](#) *J Oral Maxillofac Surg* 2003; 61:1115-1117.
33. Ruggiero SL, Mehrotra B, Rosenberg TJ, et al. [Osteonecrosis of the jaws associated with the use of bisphosphonates: A review of 63 cases.](#) *J Oral Maxillofac Surg* 2004; 62: 527-534.
34. Marx RE, Sawatari Y, Fortin M, et al. [Bisphosphonate-induced exposed bone \(osteonecrosis/osteopetrosis\) of the jaws: Risk factors, recognition, prevention, and treatment.](#) *J Oral Maxillofac Surg* 2005 ; 63 :1567-1575.
35. Migliorati CA, Siegel MA, Elting LS. Bisphosphonate-associated osteonecrosis: a long-term complication of bisphosphonate treatment. *Lancet Oncol* 2006; 7(7):508-514.
36. Wang J, Goodger NM, Pogrel MA. [Osteonecrosis of the jaws associated with cancer chemotherapy.](#) *J Oral Maxillofac Surg.* 2003; 61: 1104-1107.
37. Carboplatin. <http://www.ehealthme.com/ds/carboplatin/osteonecrosis%20of%20jaw/>. Retrieved on March 21, 2017.
38. Paclitaxel. <http://www.ehealthme.com/ds/paclitaxel/osteonecrosis%20of%20jaw/>. Retrieved on March 21, 2017.
39. Perez EA. [Paclitaxel in breast cancer.](#) *The Oncologist.* 1998; 3: 373-389.
40. Furugen M, Sekine I, Tsuta K, et al. [Combination chemotherapy with carboplatin and paclitaxel for advanced thymic cancer.](#) *Jpn J Clin Oncol.* 2011; 41: 1013-1016.
41. Pancholi M, Edwards A, Langton S. [Bisphosphonate induced osteochemonecrosis of the jaw mimicking a tumour.](#) *Br Dent J.* 2007; 203: 87-89.
42. Frei M, Bornstein MM, Schaller B, et al. Bisphosphonate-related osteonecrosis of the jaw combined with jaw metastases of prostate adenocarcinoma: report of a case. *YJOMS.* 2011; 68: 863-867.
43. Lee CYS, Lee KL, Suzuki JB. Diffuse large B-cell lymphoma mistaken for medication-related osteonecrosis of the jaw (MRONJ): a case report. *Dent Oral Craniofac Res.* 2015; 1: 36-40.
44. Bedogni A, Saia G, Ragazzo M, et al. [Bisphosphonate-associated osteonecrosis can hide jaw metastases.](#) *Bone.* 2007; 41: 942-945.
45. Welsh JS, Wilkins KB, Green R, et al. [Association between thymoma and second neoplasms.](#) *JAMA.* 2000; 283: 1142-1143.
46. Pan CC, Chen PC, Wang LS, et al. [Thymoma is associated with an increases risk of second malignancy.](#) *Cancer.* 2001; 92: 2406-2411.
47. Gander T, Obwegeser JA, Zemmann W, et al. [Malignancy mimicking bisphosphonate-associated osteonecrosis of the jaw: a case series and literature review.](#) *Oral Surg Oral Med Oral Pathol Oral Radiol.* 2014; 117: 32-36.
48. Harris CP, Barringer JR. [The numb chin in metastatic cancer.](#) *West J Med.* 1991; 155: 528-531.
49. Lesnick JA, Zallen RD. [Numb chin syndrome secondary to metastatic breast diseases.](#) *J Colo Dent Assoc.* 1999; 78: 11-14.
50. Ryba F, Rice S, Hutchison IL. [Numb chin syndrome: an ominous clinical sign.](#) *Br Dent J.* 2010; 208: 283-285.
51. Chiandussi S, Biasotto M, Dore F, et al. [Clinical and diagnostic imaging of bisphosphonate-associated osteonecrosis of the jaws.](#) *Dentomaxillofac Radiol.* 2006; 35: 236-243.
52. Dib LL, Soares AI, Sandoval RL, et al. [Breast metastases around dental implants: a case report.](#) *Clin Implant Dent Relat Res.* 2007; 9: 112-115.
53. Akinbami BO. Metastatic carcinoma of the jaws: a review of the literature. *Niger J Med.* 2009; 18: 139-142.
54. Hirshberg A, Leibovich P, Buchner A. [Metastatic tumors to the jawbones: analysis of 390 cases.](#) *J Oral Pathol Med.* 1994; 23: 337-341.
55. Cavalcanti MG, Veltrini VC, Ruprecht A, et al. [Squamous cell carcinoma arising from an odontogenic cyst- the importance of computed tomography in the diagnosis of malignancy.](#) *Oral Surg Oral Med Oral Pathol Oral Radiol Endod.* 2005; 100: 365-368.
56. Wright CD, Choi NC, Wain JC, et al. [Induction chemoradiotherapy followed by resection for locally advanced Masaoka stage III and IVA thymic tumors.](#) *Ann Thorac Surg.* 2008; 85: 385-389.
57. Kondo K, Monden Y. [Therapy for thymic epithelial tumors: a clinical study of 1,320 patients from Japan.](#) *Ann Thorac Surg.* 2003; 76: 878-884.
58. Wick MR, Scheithauer BW, Weiland LH, et al. [Primary thymic carcinomas.](#) *Am J Surg Pathol.* 1982; 6: 613-630.
59. Rios A. [Prognostic factors in thymic epithelial neoplasms.](#) *Eur J Cardiothorac Surg.* 2002; 21: 307-
60. Welsh JS, Wilkins KB, Green R, et al. [Association between thymoma and second neoplasms.](#) *JAMA.* 2000; 283: 1142-1143.