

Tuberculosis of the Prostate with Benign Prostatic Hyperplasia with Prostatitis – A Rare Presentation.

Kafil Akhtar^{*1}, Mohd Talha¹, Shivani Gupta¹, Ashok Kumar²

¹Department of Pathology, Jawaharlal Nehru Medical College, A.M.U

²Ashok Pathology and Research Center, Aligarh, India.

***Corresponding Author:** Kafil Akhtar, Professor, Department of Pathology, Jawaharlal Nehru Medical College, Aligarh Muslim University, Aligarh. (U.P)-India. E-mail: drkafilakhtar@gmail.com

Citation: Kafil Akhtar et al.(2017) Tuberculosis of the Prostate with Benign Prostatic Hyperplasia with Prostatitis – A Rare Presentation. Int J Sur &Trans Res. 1-3, 30-32

Copyright: © Kafil Akhtar et al. This is an open-access article distributed under the terms of the Creative Commons Attribution License, which permits unrestricted use, distribution, and reproduction in any medium, provided the original author and source are credited.

Received 06 May 2017; **Accepted** May 17, 2017; **Published** May 29, 2017.

Abstract

Genitourinary tuberculosis contributes to 10-14% of extrapulmonary tuberculosis and is a major health problem in India. Prostate tuberculosis is uncommon and is usually found incidentally following transurethral resection. The most common mode of involvement is haematogenous, though descending infection and direct intracanalicular extension is known. Predisposing factors include prior tubercular infection, immunocompromised status, previous BCG therapy. Apart from histopathological examination which is confirmatory to diagnosis, urine PCR with good sensitivity and specificity, may be quite helpful in the diagnosis. Imaging techniques like CT/MRI also allow good visualization of the lesion and its extension. We report a case of a 35 year old male who presented with complaints of difficulty in micturition. On digital rectal examination prostate was found to be enlarged with nodularity. TRUS biopsy showed diffuse caseating epithelioid granulomas. Treatment was given in the form of chemotherapy regimen of 4 anti-tubercular drugs. This case has emphasised the importance of considering prostatic tuberculosis in the differential diagnosis of carcinoma prostate, both of which may have the same clinical presentation. With a high index of suspicion, it may be possible to diagnose a larger number of cases of prostatic tuberculosis, especially in our country where tuberculosis is almost endemic.

Keywords: Genitourinary, Granulomatous, Hyperplasia, Infection, Prostate, Tuberculosis

Introduction

Tuberculosis is one of the major health problems with huge cost implications in India. Genitourinary tuberculosis comprises 20.0% of all extra pulmonary tuberculosis, with the prostate being involved in 70.0% of all cases.1 Amazingly, primary prostatic tuberculosis in the absence of demonstrable disease elsewhere is rare. An autopsy incidence of primary prostatic tuberculosis is only 1.0%, although the prostate is contiguous to the bladder and may be bathed in mycobacteria infested urine for a long time.2 Involvement of the prostate by tuberculosis occurs rarely and tuberculous prostate abscess is an even rarer occurrence. The diagnosis of prostatic tuberculosis can only be confirmed on histopathology. It has varied presentations and can mimic malignancy.

Case Summary

A 35 year old male presented to the surgical out patients department with few weeks history of increasing difficulty in micturition and mild perineal pain. On examination, he was afebrile and the general

physical and abdominal examination was normal. On digital rectal examination, his prostate was markedly enlarged, nodular, firm to hard in consistency and mildly tender. His blood counts were normal but his erythrocyte sedimentation rate (ESR) was raised at 55 mm in one hour. On urinalysis pyuria and microscopic haematuria was noted but urine culture was negative. Gram staining of urine did not show any bacteria. Routine biochemistry was normal. Serum PSA was 2.5ng/ml. Trans-abdominal ultrasonography showed normal upper renal tract but his prostate was slightly enlarged with irregular outline. Chest X-ray was normal. Intravenous urography showed normal upper tracts.

Mantoux test was positive with intradermal tuberculin. Urine was negative for acid fast bacilli (AFB) on three consecutive days. HIV test was negative. At cystoscopy prostate was found to be markedly enlarged and occlusive with epithelial erythema. Bladder was mildly inflamed without any trabeculations. He was thought to have some inflammatory prostatic disorder and TRUP biopsy

of the hypoechoic mass was done. On Gross multiple, firm, white tissue pieces aggregate measuring 0.5cm is seen. Microscopic examination of the prostatic tissue showed granulomatous infection with caseous necrosis compatible with tuberculosis. He was started on anti-tubercular treatment consisting of 4 drugs for 2 months, followed by 2 drugs for 7 months. After 6 months of follow up, the patient was well with no urinary symptoms.

Discussion

Tuberculosis of the prostate is a rather rare condition. Cases of tubercular prostatitis and abscess in relatively young or middle age patient with HIV infection have been reported.^{3,4} Tuberculosis of prostate results from the haematogenous spread of the microorganisms from the lungs or less often from the skeletal system.^{5,6} It may also spread from direct invasion from the urethra, but this route of infection has been questioned.^{7,8}

Tuberculosis of the prostate is usually asymptomatic except in rare cases when the disease spreads rapidly and cavitation may lead to perineal sinus.⁷ Early tubercular lesions in prostate are seldom detected on palpation, but when the disease is advanced, enlargement occurs and fluctuant tender zones may be felt bilaterally.⁸ The disease may perforate into the urethra and extend into the urinary bladder.⁹ With still further spread, sinus track may perforate into rectum, perineum and the peritoneal cavity.⁸

Advanced lesions that destroy tissue may cause a reduction in the volume of semen, a sign that may help in the diagnosis.⁹ In the present case, the patient had noticed reduction in the volume of semen for 5 months, before presenting with difficulty in micturition. Healing with calcification may supervene and large calcifications in the prostate should suggest tuberculous involvement.¹⁰ In the late stage, the prostate becomes shrunken, fibrotic and hard to the point that it may simulate carcinoma on palpation.^{8,10}

Microscopically the initial lesion is in the stroma but it quickly spreads to the acini. Initial lesion show confluent foci of caseous necrosis with epithelioid granulomas. Use of intravesical BCG for bladder carcinoma may result in caseating or non caseating tuberculous granulomas in prostate and may be located along the periurethral or transition zone or involve the gland diffusely.^{11,12}

Urinalysis and routine urine cultures are normal. Tuberculin test is almost always positive in most of the cases.¹³ In the present case report, mantoux test was positive with intradermal tuberculin. Prostate specific antigen (PSA) may be normal or increased.¹³ In our case, both PSA and prostate acid phosphatase were within normal range.

Transrectal ultrasonography (TRUS) of the prostate may reveal enlargement and hypoechoic areas in the prostatic tissue.^{9,10} Using transrectal ultrasonography, guided biopsies for histological diagnosis can be taken and abscess drainage can be accomplished.¹⁰

Wang et al⁸ have demonstrated the clinical usefulness of contrast enhanced CT for the diagnosis of tuberculosis of prostate, in which low density multiple and bilateral lesions with irregular borders are seen. Magnetic resonance imaging (MRI) for the diagnosis of

the tuberculous prostate has been described.^{8,9} MRI has certain advantages over CT including better resolution and multiplanar imaging capabilities. In prostatic tuberculosis, diffuse radiating streaky low signal intensity lesions are seen in the prostate (watermelon skin sign), which are quite different from MRI findings of carcinoma of prostate.^{8,9} Although imaging examinations may be helpful in the diagnosis, a definite diagnosis is made by histologic examination of the prostatic biopsy specimen.

Two important points for the clinicians regarding tuberculosis of prostate are firstly, viable organisms frequently persist long after other parts of the genitourinary system have been sterilized and secondly tuberculosis can be transmitted by means of infected semen in such patients.^{14,15} Sometimes the diagnosis of the husband's disease may be made only after the lesion has appeared in the wife. A painful swelling of the inguinal glands in female that proves to be tuberculous should alert the clinician to the possible diagnosis of genital tract tuberculosis in the male partner.¹⁵ Treatment of prostatic tuberculosis, once the diagnosis is confirmed, is complete course of anti-tubercular drugs.⁹ Surgery is usually reserved for cases where chemotherapy fails and is done after 4-6 weeks of anti-tubercular therapy.

Although most cases of tuberculosis of prostate are diagnosed after prostatectomy, but it can occur in healthy young males with no respiratory symptoms or immune deficiency as a primary prostatic tuberculosis.^{15,16} Prostatic tuberculosis has a varied clinical presentation and is an important cause of granulomatous prostatitis especially in developing countries.^{14,16} The presentation may range from asymptomatic prostatic abscess (due to spread of abdominal tuberculosis to genitourinary tract) or may be associated with testicular swelling and rectal sinus in rare case.^{9,13} Probably several cases of tuberculosis of prostate remains undiagnosed. This condition must be considered in cases of tuberculosis of genitourinary tract and appropriate investigations should be carried out to diagnose it.

The differential diagnosis of tuberculosis of the prostate are prostatic carcinoma, benign prostatic hyperplasia, malakoplakia and pyelonephritis. Our patient was 35 years old. Prostatic cancer was easily ruled out, as it is a disease of old age (above 50 years), seen in peripheral zone of glands with high serum PSA level (>10ng/ml) and show perineural and angio-lymphatic invasion, with closely packed infiltrating small to medium sized crowded glands with atypical glandular cells on microscopy. Benign prostatic hyperplasia is seen in middle aged males of more than 40 years and is associated with obstructive symptoms of urination, such as urgency, dribbling of urine, nocturia and dysuria and on microscopy shows diffuse hyperplasia of glandular and stromal elements. Our case had a foci of benign prostatic hyperplasia. Malakoplakia is a nonspecific tissue reaction of the prostate gland to gram negative bacteria, usually E coli. It is more common after 45 years of age, easily diagnosed by von kossa stain and on microscopy show michaelis gutmann body along with iron and calcium deposition in tissue. Pyelonephritis can be ruled out easily, as it shows dilated and distorted calyces and pelvis on IVP.

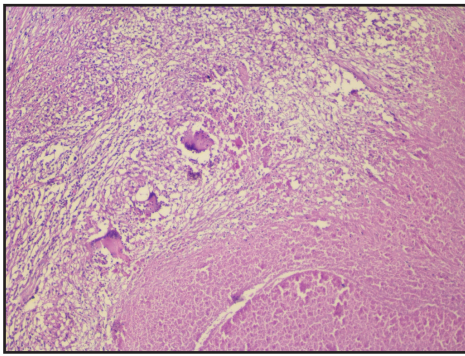


Figure 1

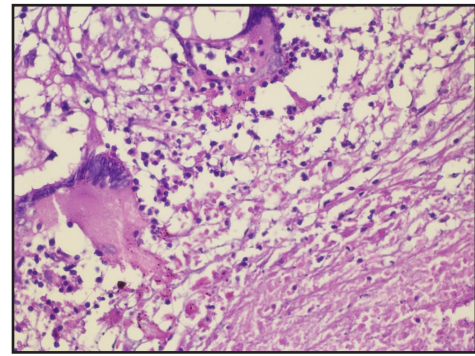


Figure 2

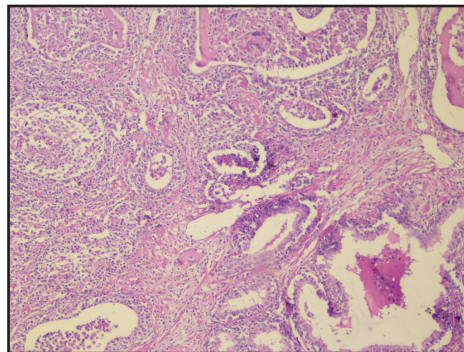


Figure 3

Conclusion

Tuberculosis of the prostate is relatively rare. Prostatic tubercular lesions are most commonly secondary to a primary foci. A thorough examination to rule out other primary sites should be attempted. With the recent increase in the incidence of tuberculosis, clinicians need to be aware of this possibility, consider tuberculosis of prostate in the differential diagnosis of prostatic carcinoma and thus, play a role in the early detection of this disease.

References

1. Kulchavenya E, Brizhatyuk E, Khomyakov V. Diagnosis and therapy for prostate tuberculosis. *Ther Adv Urol* 2014; 6(4): 129-134.
2. Trauzzi SJ, Kay CJ, Kaufman DG. Management of prostatic abscess in patients with human immunodeficiency syndrome. *Urol* 1994; 43: 629-633.
3. Chan WC and Thomas M. Prostatic abscess: another manifestation of tuberculosis in HIV- infected patients. *Aust NZ J Med* 2000; 30:94-95.
4. Juan Rosai. Male reproductive system. In: *Ackerman's Surgical Pathology*, St. Louis: Mosby, 12th ed, 2012; pp121-123.
5. Gow JG. Genitourinary tuberculosis. In: *Campbell's Urology*. Walsh PC, Retik AB, Vaughan EA, Wein AJ 7th ed, Philadelphia: WB Saunders, 2010; pp 807-836.
6. Tanagho EA. Specific infections of the genitourinary tract. In: *Smith's General Urology*. EA Tanagho, JW McAninch 15th ed. New York: McGraw-Hill, 2010; pp 265-281.
7. Kostakopoulos A, Economou G, Picramenos D. Tuberculosis of the prostate. *Int Urol Nephrol* 2008; 30:153-157.
8. Wang JH, Sheu MH, Lee RC. Tuberculosis of the prostate: MR appearance. *J Comput Assist Tomog* 2007; 21:639-640.
9. Gupta S, Khumukcham S, Lodh B, Singh AK. Primary prostatic tuberculosis: A rare entity. *J Med Soc* 2013; 27: 84-86.
10. Shukla P, Gulwani H, Kaur S. Granulomatous prostatitis in a tertiary care hospital. *Prostate Int* 2017; 5:29-34.
11. Cavalli Z, Ader F, Chidiac C, Ferry T. Asymptomatic prostatic tuberculous abscess in an immunocompetent man with peritoneal tuberculosis. *BMJ Case Reports* 2015; 15:15-17.
12. Kumar S, Kashyapi BD, Bapat SS. Tuberculosis of the prostate. *Int J Surg Case Reports* 2015; 10:80-82.
13. Yaqeen Esa N, Hanafiah M, Koshy M, Abdullah H, Ismail AI, Abdul Rani MF. A Rare Case of Tuberculous Prostatitis. *J Clin Health Sci* 2016; 1:33-36.
14. Aziz ME, Abdelhak K, Hassan MF. Tuberculous prostatitis: mimicking a cancer. *Pan Afr Med J* 2016; 25:130-132.
15. Mumu MA, Rahman MT, Hossain A, Banu S, Karim MM. Tuberculous prostatitis is in prostatic cancer patients in Bangladesh. *Bioresearch Comm* 2016; 2:275-278.
16. Kulchavenya E, Kholtohin D. Prostate Tuberculosis as predisposition for Prostate Cancer. *Clin Res Infect Dis* 2015;2(1):1-3.